Pemphigoid Group 30

Luca Borradori and Michael Hertl

Chapter Contents

Bullous Pemphigoid 517
Mucous Membrane Pemphigoid 526
Epidermolysis Bullosa Acquisita 530

BULLOUS PEMPHIGOID

Synonym: ▪ Pemphigoid

Key features

- Bullous pemphigoid (BP) is the most common autoimmune subepidermal blistering disease, and its onset is often after 60 years of age
- It is usually a chronic disease, with spontaneous exacerbations and remissions, which may be accompanied by significant morbidity
- BP is associated with tissue-bound and circulating autoantibodies directed against BP antigen 180 (BP180, BPAG2, or type XVII collagen) and BP antigen 230 (BP230 or BPAG1e), components of junctional adhesion complexes called hemidesmosomes that promote dermal–epidermal cohesion
- The spectrum of clinical presentations is extremely broad. Characteristically, BP is an intensely pruritic eruption with widespread blister formation. In its early stages, or in variants of the disease, only eczematous or urticarial lesions (either localized or generalized) or just excoriations due to intense pruritus are present
- Diagnosis relies on immunopathologic examinations, particularly direct and indirect immunofluorescence (IF) microscopy as well as ELISA for anti-BP180/BP230 autoantibodies

Introduction

Bullous pemphigoid (BP) is the most common autoimmune subepidermal blistering disease. It typically presents in older adults as a generalized pruritic bullous eruption and is often associated with significant morbidity. The clinical presentation is quite polymorphic, particularly during the early stages of the disease or in atypical variants, in which full-blown bullous lesions may be absent. In these cases, establishing the diagnosis of BP requires a high degree of suspicion. The antigens targeted by patients' autoantibodies represent two components of hemidesmosomes, the junctional adhesion complexes found in skin and adjacent mucosae (see Fig. 28.3A).

History

In 1953 Lever recognized BP as a disorder distinct from the various types of "true" pemphigus based upon specific clinical and histopathologic features[1]. A decade later, Jordon, Beutner, and colleagues[2] demonstrated that BP patients had tissue-bound and circulating autoantibodies directed against the cutaneous basement membrane zone (BMZ), an observation that suggested that subepidermal dysadhesion was due to autoantibodies directed against structural components of the skin[2]. Further milestones in our understanding of BP included the immunochemical characterization of targeted proteins, the cloning of their genes, and the development of animal models of the disease[3–5].

Epidemiology

BP is typically a disease of older adults, with a mean age of presentation between 65 and 85 years. The annual incidence has been estimated to range from 5 to 45 new cases per million population per year. The incidence rate of BP appears to have significantly increased over the past two decades, most likely reflecting an aging population, better recognition of atypical variants, and a rise in drug-induced BP[6]. A relative risk for patients over 90 years of age appears to be ~300-fold higher than for those 60 years of age or younger. The disease also occurs in children, but rarely. Certain HLA class II alleles are more prevalent in patients with BP than in the general population[7]. In Caucasians, a significant association with the allele DQB1*0301 has been noted, while an increased frequency of the alleles DRB1*04, DRB1*1101, and DQB1*0302 has been observed in Japanese patients.

Pathogenesis

BP is an example of an immune-mediated disease that is associated with a humoral and cellular response directed against two well-characterized self-antigens: BP antigen 180 (BP180, also known as BPAG2 or type XVII collagen) and BP antigen 230 (BP230, also referred to as the epithelial isoform of BPAG1 [BPAG1e]) (Table 30.1)[3,4]. While the former is a transmembrane protein with a large collagenous extracellular domain, the latter is a cytoplasmic protein belonging to the plakin family (see Ch. 28). These two antigens are components of the hemidesmosomes, which are adhesion complexes promoting epithelial–stromal adhesion in stratified and other complex epithelia.

In vitro studies and *in vivo* animal models have demonstrated the pathogenic role of autoantibodies in BP. Furthermore, in gestational pemphigoid, a disease closely related to BP, the transplacental transfer of anti-BP180 autoantibodies from the mother to the neonate can result in a transient bullous eruption (see Ch. 34).

Humoral and cellular responses

Almost all patients with BP have circulating IgG autoantibodies that bind to BP180. Specifically, it is the non-collagenous NC16A domain, a region of BP180 located extracellularly but close to the transmembrane domain, that constitutes the immunodominant region (see Fig. 31.9)[8,9]. However, additional antigenic sites exist within both the extracellular and intracellular domains of BP180, and they are recognized by up to 70% of BP sera[8,9]. Patients with BP also exhibit significant autoreactivity to BP230, and BP230-reactive autoantibodies bind predominantly to the COOH-terminal region of this autoantigen[4,8,9]. The presence of several antigenic sites throughout BP180 and BP230 most likely results from the phenomenon known as "epitope spreading" (see below)[9]. This phenomenon may also account for the finding that patients' sera rarely contain autoantibodies targeting additional components of the BMZ.

Patients with BP develop an autoreactive T cell response to BP180 and BP230. Likely related to a dysfunction of regulatory T cells, it is crucial for stimulating B cells to produce autoantibodies[10,11]. The responsiveness of anti-BP180 autoreactive T cells is restricted by certain HLA class II alleles (e.g. HLA-DQB1*0301), which are prevalent in BP patients. These T lymphocytes, whose major relevant epitopes seem to be harbored within the NC16 domain, have a $CD4^+$ phenotype and produce both Th1 (e.g. interferon-γ) and Th2 cytokines (e.g. interleukin [IL]-4, IL-5, IL-13; see Ch. 4)[10,11]. Th2 and Th17 cytokines, which are particularly relevant to the pathophysiology of BP, predominate within lesional tissue and in patients' sera[10–13].

Upon binding of autoantibodies to their target antigens, subepidermal blister formation results from a cascade of events in which Fc

Downloaded for Anonymous User (n/a) at Egyptian Knowledge Bank from ClinicalKey.com by Elsevier on March 10, 2024. For personal use only. No other uses without permission. Copyright ©2024. Elsevier Inc. All rights reserved.

MAJOR AUTOANTIGENS OF SUBEPIDERMAL AUTOIMMUNE-MEDIATED BLISTERING DISEASES			
Disease	**Target antigen(s)**	**Mol. wt. (kDa)**	**Morphologic structures**
Bullous pemphigoid (BP)	BP180/BPAG2/collagen XVII BP230/BPAG1e	180 230	Hemidesmosomal plaque/anchoring filaments Hemidesmosomal plaque
Gestational pemphigoid	BP180/BPAG2/collagen XVII BP230/BPAG1e	180 230	Hemidesmosomal plaque/anchoring filaments Hemidesmosomal plaque
Mucous membrane pemphigoid	BP180/BPAG2/collagen XVII BP230/BPAG1e[†] Laminin 332 (laminin 5; $\alpha_3\beta_3\gamma_2$; epiligrin) Laminin 311 (laminin 6; $\alpha_3\beta_1\gamma_1$)[‡] Integrin β_4 subunit[§] Integrin α_6 subunit[§] LABD97, LAD-1 Type VII collagen[†]	180 230 165, 140, 105 165, 220, 200 200 120 97, 120 290/145	Hemidesmosomal plaque/anchoring filaments Hemidesmosomal plaque Anchoring filaments Anchoring filaments/extracellular matrix Hemidesmosomal plaque/anchoring filaments Anchoring filaments Anchoring fibrils
Linear IgA bullous dermatosis (LABD)	LABD97, LAD-1[¶] BP180/BPAG2/collagen XVII BP230/BPAG1e[†] Type VII collagen[†]	97, 120 180 230 290/145	Anchoring filaments Hemidesmosomal plaque/anchoring filaments Hemidesmosomal plaque Anchoring fibrils
Epidermolysis bullosa acquisita	Type VII collagen	290/145	Anchoring fibrils
Anti-p200 pemphigoid (anti-laminin γ1 pemphigoid)	Laminin γ1 chain*	200	Extracellular matrix
Bullous systemic lupus erythematosus	Type VII collagen[†]	290/145	Anchoring fibrils
Lichen planus pemphigoides	BP180/BPAG2/collagen XVII BP230/BPAG1e[†]	180 230	Hemidesmosomal plaque/anchoring filaments Hemidesmosomal plaque

*Major target antigen; additional target antigens, which may be critical in the pathogenesis, have been identified in one-third of cases.
[†]Detectable in a subset of patients.
[‡]Binding to laminin 311 depends on the presence of cross-reactive autoantibodies directed against the α-chain of laminin 332 (laminin 5).
[¶]They constitute the most characteristic serologic marker for LABD. The 120 kDa LAD-1 antigen corresponds to the cleaved, shed extracellular domain of BP180/BPAG2. The 97 kDa LABD97 protein results from its further proteolytic degradation (see Fig. 31.9).
[§]Reactivity against the α_6 and β_4 subunits of the $\alpha_6\beta_4$ integrin have been described in subsets of patients with oral- and ocular-predominant MMP, respectively. The significance of these autoantibodies remains to be validated.

Table 30.1 Major autoantigens of subepidermal autoimmune-mediated blistering diseases. Not an exhaustive list. In the course of these diseases, it is possible to detect autoantibodies directed against additional antigens, the significance of which remains to be established. In certain cases, a so-called "intermolecular epitope spreading" phenomenon is thought to occur.

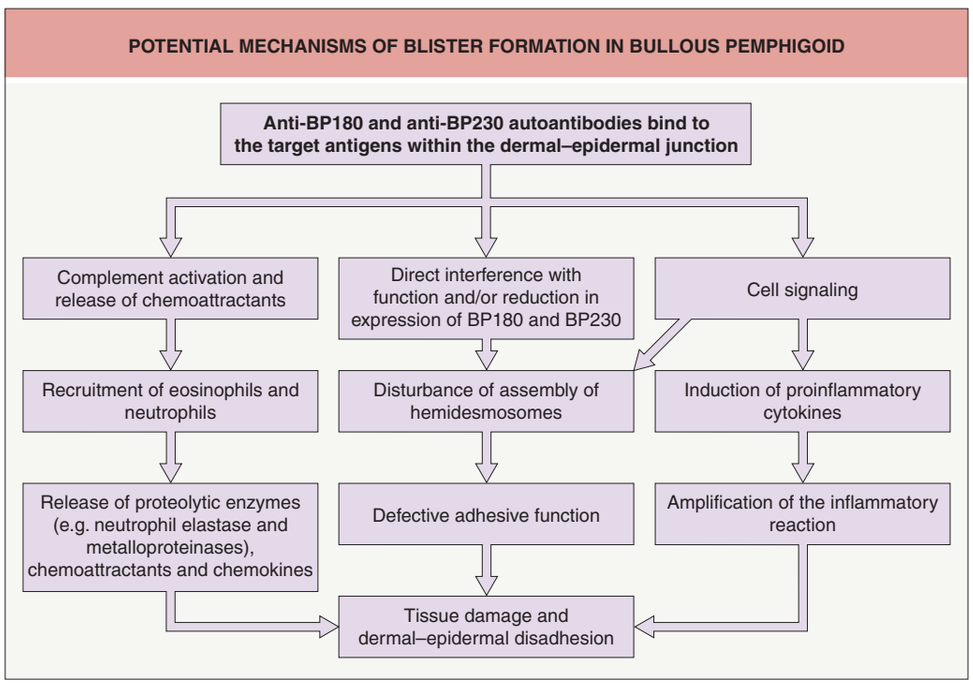

Fig. 30.1 Potential mechanisms of blister formation in bullous pemphigoid. IgG autoantibodies are classically involved in the pathogenesis, but more recently IgE autoantibodies have also been described. The latter may directly trigger the degranulation of FcεRI-expressing cells, such as eosinophils and mast cells.

receptor-mediated mechanisms are critical[5,11,14–18]. The latter involve activation of the complement cascade along with stimulation and recruitment of inflammatory cells including macrophages, neutrophils, mast cells, and eosinophils. These inflammatory cells contribute to tissue damage via liberation of various proteases (e.g. matrix metalloproteinase-9, neutrophil elastase, mast cell proteases), eosinophil toxic granules, and a variety of cytokines (e.g. IL-4, -5, -8, -13, -17, eotaxin). The latter serve to further amplify the inflammatory response[5,11–16] while the proteinases, together with reactive oxygen species, degrade various extracellular matrix proteins as well as BP180.[11–16] IgG anti-BP180 autoantibodies can also boost the inflammatory response by stimulating keratinocytes to express inflammatory cytokines (Fig. 30.1)[11]. Furthermore, IgG autoantibodies are able to directly impair dermal–epidermal adhesion without complement activation[11].

Downloaded for Anonymous User (n/a) at Egyptian Knowledge Bank from ClinicalKey.com by Elsevier on March 10, 2024. For personal use only. No other uses without permission. Copyright ©2024. Elsevier Inc. All rights reserved.

Finally, BP patients often have circulating IgE anti-BP180 autoantibodies which may bind to the epidermal BMZ. These IgE autoantibodies also seem able to form complexes with shed BP180 fragments, which are prominently detected in the dermis on the surface of mast cells and/or eosinophils expressing FcεRI. Hence, IgE autoantibodies most likely directly contribute to tissue damage by triggering the degranulation of these FcεRI-expressing cells[11,15,16].

Animal models have provided strong evidence that IgG autoantibodies against BP180 are pathogenic[5,11,14,17,18]. When passively transferred to neonatal mice (in which BP180 had been fully or partially humanized by genetic engineering), human autoantibodies against the NC16A domain were able to induce a blistering disorder that reproduced all the key features of BP[11,17]. In addition, passive transfer experiments in mice have indicated that IgE antibodies directed against BP180 contribute to skin inflammation[15]. The prevailing pathomechanism is that antibodies against the ectodomain of BP180 are critical for disease initiation, while the development of antibodies against BP230 represents a secondary event that contributes to tissue damage[9,11,18]. However, recent studies utilizing a mouse model demonstrated that anti-BP230 antibodies also had a direct pathogenic effect[19].

Clinical Features

Non-bullous pemphigoid

The cutaneous manifestations of BP can be extremely polymorphic (Figs. 30.2–30.6)[1,18,20–22]. In the prodromal, non-bullous phase of the disease, signs and symptoms are frequently nonspecific, but mild to severe intractable pruritus is a consistent feature. Clinical findings vary from excoriations to eczematous, papular, and/or urticarial lesions that have persisted for several weeks or months (see Figs. 30.3 to 30.5). Importantly, these nonspecific skin findings may remain as the only signs of the disease. At least 20% of patients have neither obvious blisters nor erosions due to ruptured bullae at the time of diagnosis[18,20,22].

Bullous phase

The bullous stage of BP is characterized by the development of vesicles and bullae on apparently normal or erythematous skin, together with urticarial and infiltrated papules and plaques that occasionally assume an annular or figurate pattern. The blisters are tense, up to 1–4 cm in diameter, contain a clear fluid, and may persist for several days, leaving eroded and crusted areas (see Fig. 30.2). Occasionally, the blister fluid becomes blood-tinged. The lesions frequently have a symmetric distribution pattern, and they predominate on the flexural aspects of the extremities and the lower trunk, including the abdomen. Within intertriginous zones, vegetating plaques may be observed (pemphigoid vegetans; see Fig. 30.6C). The extent and degree of disease activity can be assessed by employing the BP disease area index (BPDAI)[21] or a daily blister count.

Residual postinflammatory changes include hyper- and hypopigmentation and, less commonly, milia. Involvement of the oral cavity is observed in 10%–30% of patients, more often in those with moderate to severe disease. The mucosae of the eyes, nose, pharynx, esophagus, and anogenital region are more rarely affected. In ~50% of patients, a peripheral blood eosinophilia is noted.

Clinical variants

Several clinical forms of BP have been described and are outlined in Table 30.2[18,20,22]. *Gestational pemphigoid* (pemphigoid gestationis) is also a variant of BP, which typically occurs during pregnancy (see Ch. 27).

While the individual lesions of BP in infants and in older children (*infantile* and *childhood BP*) are similar to those observed in older adults, the sites of involvement can differ (Fig. 30.7). In infants, bullae often first appear in acral locations and then can generalize to other sites, including often the face. Involvement of the genital region (e.g. *vulvar childhood pemphigoid*) as well as other mucosal sites has been observed in children[18,20].

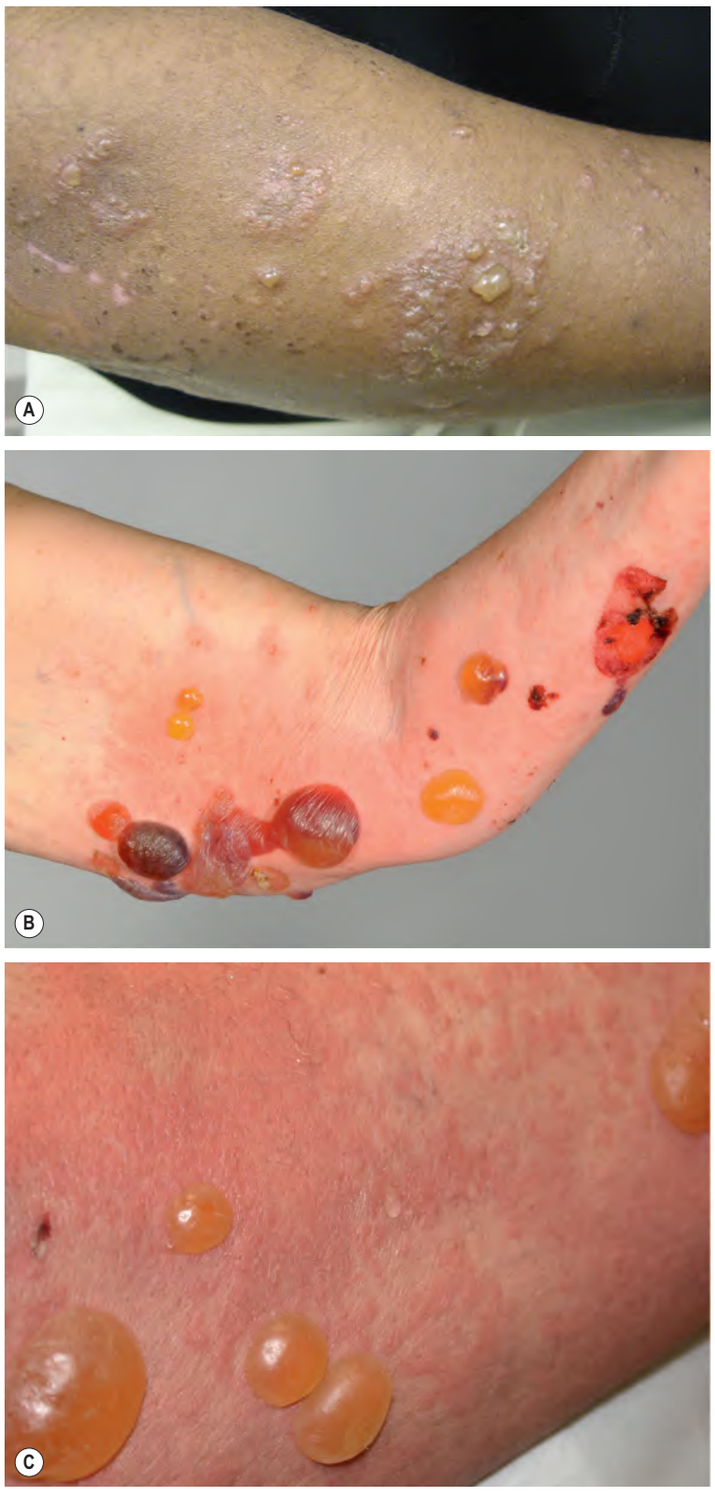

Fig. 30.2 Bullous pemphigoid – classic presentation. A–C Tense vesicles and bullae vary in size from a few mm to several cm in diameter and can arise within normal-appearing skin, areas of erythema, or urticarial plaques. The blister fluid may be serous or hemorrhagic. The flexor aspect of the extremities is a common site of involvement. As the bullae age, they become flaccid and rupture, leaving erosions and serous or hemorrhagic crusts. Biopsies of vesiculobullae for routine histology should be obtained from the edge of a fresh tense blister. *Jeffrey Callen, MD.*

Associated Diseases

The association of internal malignancies with BP is probably related primarily to the older age of the patient. In case–control studies, the trend towards an increased risk of malignancy was marginal[18,20] while an English national record linkage study found no overall increased risk for concurrent or subsequent malignancies in BP patients[23]. Nonetheless, individuals with BP should be up to date with age-related cancer screening tests recommended for the general population.

Rarely, BP has been described in patients with inflammatory bowel disease or other autoimmune diseases including Hashimoto thyroiditis,

Downloaded for Anonymous User (n/a) at Egyptian Knowledge Bank from ClinicalKey.com by Elsevier on March 10, 2024. For personal use only. No other uses without permission. Copyright ©2024. Elsevier Inc. All rights reserved.

Fig. 30.3 Bullous pemphigoid – urticarial presentation. Multiple, firm annular, arciform and polycyclic urticarial plaques. Note the absence of bullae.

Fig. 30.4 Bullous pemphigoid – eczematous presentation. Large pink eczematous plaques on the trunk and upper extremities.

rheumatoid arthritis, dermatomyositis, and lupus erythematosus (LE)[18,20,23,24]. These associations may be fortuitous or they could reflect a genetically determined susceptibility to develop autoimmune disorders. While one case–control study did not find an increased risk for autoimmune diseases[24], a sample analysis of US hospitalized patients with BP reported a slight risk for other autoimmune disorders[25].

In some patients, BP appears to be triggered by trauma, burns, radiotherapy or UV irradiation (including PUVA). BP has also been observed in association with certain dermatoses, in particular lichen planus and psoriasis (Fig. 30.8)[18,20]. In *lichen planus pemphigoides*, BP coexists with lichen planus (see Ch. 11). Theoretically, a dysfunction of T regulatory cells leads to both a lichenoid interface dermatitis and an autoantibody response to BP180 and BP230. In the setting of chronic inflammation at the dermal–epidermal junction, exposure of antigens to autoreactive T lymphocytes could result in a secondary immune response[26].

Finally, BP has been strongly associated with psychiatric and neurologic disorders; the latter include Parkinson disease, dementia, multiple sclerosis, and stroke[27]. It should be noted that a neuronal variant of BP230 is expressed in the central and peripheral nervous systems[19], while available data regarding the expression of BP180 are contradictory. Whether exposure to neuronal antigens, via a compromised blood–brain barrier, plays a role in the development of BP remains to be determined.

Fig. 30.5 Bullous pemphigoid – nonspecific lesions due to pruritus. Multiple excoriations and nonspecific lesions of prurigo simplex are present. Bullous pemphigoid is in the differential diagnosis of chronic pruritus associated with secondary excoriations.

Drug-induced bullous pemphigoid

In certain patients, systemic medications can lead to the development of BP (Fig. 30.9)[28,29]. There are multiple implicated drugs, in particular diuretics (e.g. furosemide), NSAIDs, antibiotics (e.g. amoxicillin, ciprofloxacin), ACE inhibitors, and TNF inhibitors. More recently, dipeptidyl peptidase-4 inhibitors (e.g. vildagliptin, linagliptin) and immune checkpoint inhibitors (e.g. nivolumab, pembrolizumab) have been strongly associated with BP. A meta-analysis suggested that exposure to aldosterone antagonists, dipeptidyl peptidase-4 inhibitors, anticholinergics, and dopaminergic medications were significantly associated with BP[28]. Therefore, a detailed history is essential. Discontinuation of the drug, or a drug holiday in the case of immune checkpoint inhibitors, may or may not lead to improvement[22,29a]. As a result, initiation of standard therapies may be required.

A number of hypotheses have been put forth to explain drug-induced BP – an underlying genetic predisposition, medication-related alteration of the antigenic properties of the BMZ[28,29], and a breakdown of immune tolerance in the case of immune checkpoint inhibitors. In dipeptidyl peptidase-4 inhibitor-induced BP, autoantibodies also recognize BP180 epitopes other than the NC16A domain.

Diagnosis

The diagnosis of BP is based upon the typical clinical presentation, compatible histologic features, and, most importantly, positive direct immunofluorescence (DIF) microscopy studies (see Fig. 29.17)[18,20–22]. Further support for the diagnosis of BP requires the detection of specific circulating IgG autoantibodies (anti-BP180, anti-BP230) via either indirect immunofluorescence (IIF) microscopy or ELISA. In the vast majority of patients, these tests allow for the correct classification of patients. However, in a minority of patients (~10%) in whom both IIF microscopy and ELISA are negative, additional immunopathological studies, e.g. n-serration *versus* u-serration pattern analysis (see below), can be employed to demonstrate indirectly an autoantibody response to BP180 and/or BP230 and thereby exclude other autoimmune bullous diseases (see Table 30.1)[12,20,22].

Light microscopy

In the non-bullous phase or in atypical variants of BP, routine histology may provide less specific information, since only eosinophilic spongiosis and/or dermal inflammatory infiltrates admixed with numerous eosinophils may be seen (Fig. 30.10)[18,20,22]. In biopsy specimens of an early bulla, a subepidermal blister accompanied by a dermal inflammatory infiltrate composed of eosinophils and mononuclear cells is typically observed. The infiltrate favors the uppermost dermis, and the cavity of the bulla contains a net of fibrin with a variable inflammatory

Downloaded for Anonymous User (n/a) at Egyptian Knowledge Bank from ClinicalKey.com by Elsevier on March 10, 2024. For personal use only. No other uses without permission. Copyright ©2024. Elsevier Inc. All rights reserved.

Fig. 30.6 Bullous pemphigoid – uncommon clinical variants. A, B In dyshidrosiform pemphigoid, clusters of vesicles and bullae appear on acral skin and can resemble dyshidrotic eczema or pompholyx. **C** In pemphigoid vegetans, vegetating plaques can develop in major body folds, including the inguinal crease. **D** Toxic epidermal necrolysis-like lesions with large erosions.

UNUSUAL CLINICAL VARIANTS OF BULLOUS PEMPHIGOID	
• Dyshidrosiform pemphigoid – palmoplantar vesicles and bullae (Fig. 30.6A,B)	
• Pemphigoid vegetans – intertriginous vegetating plaques (Fig. 30.6C)	
• Pemphigoid nodularis – prurigo nodularis-like lesions	
• Vesicular pemphigoid – dermatitis herpetiformis-like presentation with small grouped vesicles	
• Large erosive TEN-like lesions (Fig. 30.6D)	
• Papular pemphigoid	
• Eczematous pemphigoid (Fig. 30.4)	
• Erythrodermic pemphigoid	
• Lichen planus pemphigoides (see Fig. 11.9C)	
• Acquired reactive perforating dermatosis-like	
• *Localized forms:*	
• pretibial	• distal end of amputated limb*
• vulvar	• paralyzed limb
• peristomal	• sites of radiotherapy†
• umbilical	• Brunsting–Perry form‡
*Also referred to as "stump" pemphigoid.	
†Radiotherapy can also provoke generalized form of pemphigoid.	
‡Also variant of mucous membrane pemphigoid.	

Table 30.2 Unusual clinical variants of bullous pemphigoid.

infiltrate (Fig. 30.11). Conventional electron microscopy studies have shown that subepidermal blister formation usually occurs at the level of the lamina lucida.

Direct immunofluorescence (DIF) microscopy

In almost all patients, DIF microscopy of *perilesional* skin, either normal-appearing or if inflamed 1–2 cm from a bulla, will characteristically demonstrate the presence of fine, linear, continuous deposits of IgG and/or C3 (and, more rarely, other Ig classes) along the epidermal basement membrane (see Fig. 1.9)[18,20,22]. IgG4 and IgG1 are the predominant IgG subclasses. Two additional studies are helpful in distinguishing BP from other autoimmune blistering disorders: (1) close analysis of the linear fluorescence pattern at the BMZ in order to determine if it is *n-serrated* (BP and linear IgA bullous dermatosis) versus *u-serrated* (epidermolysis bullosa acquisita)[30]; and (2) the salt-split skin assay in which perilesional skin is examined after treatment with 1 M NaCl (see Fig. 28.7)[18,20,22]. In BP, immune deposits are found in the epidermal side (roof) or in both the epidermal and dermal sides of the split. Although not routinely available, the computer-aided fluorescence overlay antigen mapping (FOAM) technique allows for more precise localization of the deposited immunoreactants.

Indirect immunofluorescence (IIF) microscopy

For IIF studies in subepidermal blistering diseases, salt-split normal human skin is the substrate of choice, rather than intact normal human skin or monkey esophagus (see Table 29.5). Circulating anti-basement membrane autoantibodies of the IgG class, and less frequently of the IgA and IgE classes, are detectable in 60%–80% of patients[18,20]. These autoantibodies typically bind to the epidermal side or, less frequently, to both the epidermal and dermal sides of saline-separated normal human skin (Fig. 30.12). In a single miniature incubation field, multiplex tests that combine IIF with BIOCHIP technology have been used to screen for autoantibodies against multiple target antigens[31].

ELISA

An increasing number of autoantibodies associated with autoimmune bullous diseases can be detected via ELISA (see Table 29.6). Target antigens include the NC16A domain of BP180 and the COOH-terminus (± the NH2-terminus) of BP230[8,9,18,20,22]. In the case of BP, these tests have been found to be fairly *specific* (≥90%); occasionally, low-titer, false-positive results are observed in healthy subjects and elderly patients with pruritic cutaneous eruptions[18]. When performed in unselected BP patients, the overall *sensitivity* of the BP180–NC16A ELISA is comparable to that of IIF (with salt-split human skin as a substrate)[9,18,20,31]. Combining the ELISA for BP230 with the BP180–NC16A ELISA increases the overall sensitivity by ~10% so the former

Downloaded for Anonymous User (n/a) at Egyptian Knowledge Bank from ClinicalKey.com by Elsevier on March 10, 2024. For personal use only. No other uses without permission. Copyright ©2024. Elsevier Inc. All rights reserved.

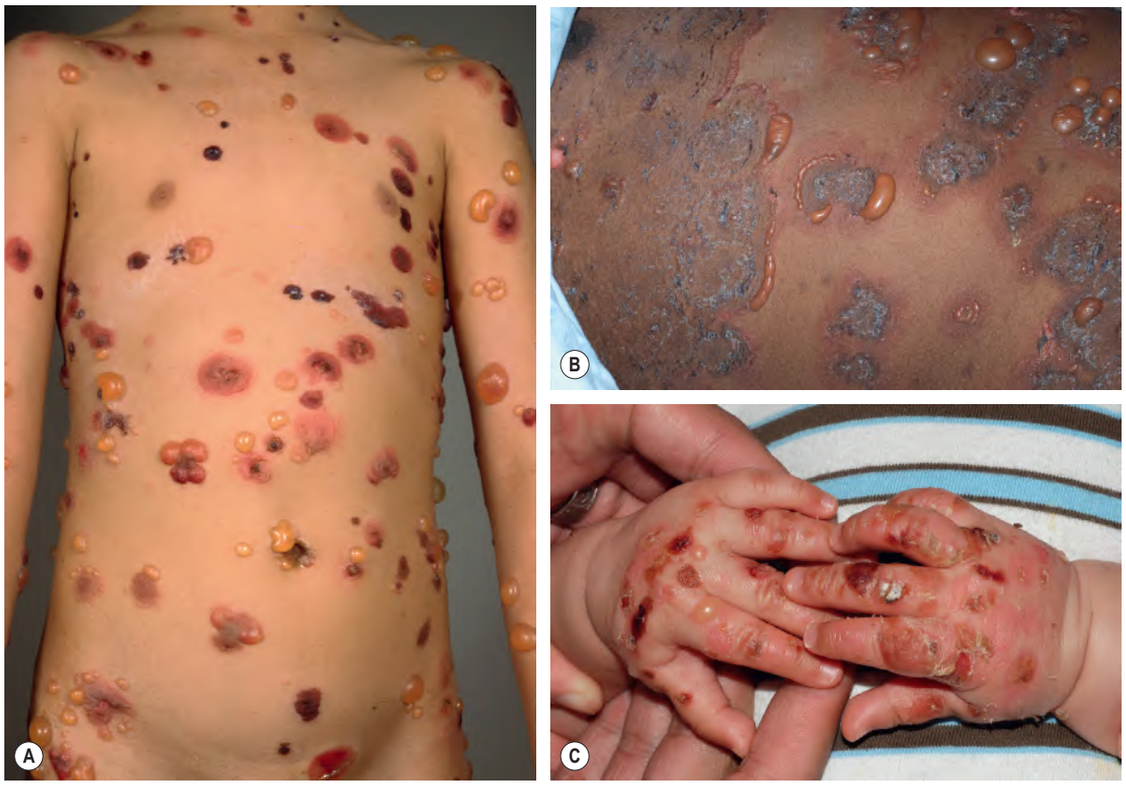

Fig. 30.7 Childhood bullous pemphigoid. A Generalized tense bullae and circular crusted erosions. **B** Tense vesicles and bullae in an annular or figurate array at the edge of expanding lesions, a presentation that might be diagnosed clinically as linear IgA bullous dermatosis. **C** A predominance of acral involvement is often seen in infants. *B, C, Courtesy Julie V. Schaffer, MD.*

Fig. 30.8 Bullous pemphigoid localized to a psoriatic plaque. No obvious trigger was detected, as the patient was not receiving phototherapy. *Courtesy Jean L. Bolognia, MD.*

is only recommended in the setting of a negative BP180 ELISA[32]. A multivariant ELISA that contains multiple autoantigens and utilizes BIOCHIP technology has recently been introduced[33].

Other immunopathological studies

In immunoblot and immunoprecipitation studies of keratinocyte extracts, which are not commercially available, 60%–100% of patients' sera contain IgG autoantibodies that bind to BP180 and BP230, respectively (Fig. 30.13A,B). Patients' sera also frequently contain specific IgA and IgE autoantibodies. In general, recombinant forms of BP180 and BP230 expressed in prokaryotic or eukaryotic systems are used for the detection of autoantibodies (Fig. 30.13C)[9,10,18,20].

Differential Diagnosis

Because the clinical findings in the non-bullous forms of BP may be nonspecific, they can resemble a variety of dermatoses, including drug reactions, contact dermatitis, prurigo (simplex and nodularis), urticarial dermatoses, arthropod reactions, and scabies[18,20,22]. These disorders are usually distinguished on the basis of the clinical history and setting, pathologic features, and the negative findings with IF microscopy. The presence of bullae raises the possibility of bullous arthropod bites and the eosinophilic dermatosis of hematologic malignancy, allergic contact dermatitis, bullous drug eruptions (see Ch. 33), dyshidrotic eczema, pseudoporphyria, or porphyria cutanea tarda. In children, bullous impetigo, inherited epidermolysis bullosa, and bullous mastocytosis must also be considered.

The pemphigus group, paraneoplastic pemphigus, and dermatitis herpetiformis can be differentiated on the basis of distinctive immunopathologic findings and clinical context. In patients with a subepidermal blistering disorder associated with linear deposits of IgG or C3 along the BMZ, the presence of the following clinical criteria point to the diagnosis of BP: (1) absence of skin atrophy; (2) absence of mucosal involvement; (3) absence of head and neck involvement; and (4) age greater than 70 years[18,20,22]. Nevertheless, the distinction of BP from the following disorders can sometimes prove challenging (see Table 30.1).

- **Epidermolysis bullosa acquisita (EBA)** has a wide spectrum of clinical presentations (see below). While the classic "non-inflammatory" form of EBA is sufficiently distinctive, the "inflammatory" form closely mimics BP. As in BP, mucosal involvement may be present[18,20].
- **Linear IgA bullous dermatosis (LABD)** represents a group of subepidermal blistering diseases rather than a single entity (see Ch. 31). While features of LABD are polymorphic in adults, during childhood the condition is frequently associated with annular and polycyclic lesions, often with peripheral blisters, as well as involvement of the genital and perioral region. However, identical features are also observed in childhood BP (see Fig. 30.7B)[18,20].
- **Anti-p200 pemphigoid (anti-laminin γ1 pemphigoid)**. Although patients often have features similar to BP, they tend to be younger and are more likely to have involvement of palmoplantar and cephalic regions as well as the oral mucosa. Neutrophils are usually the predominant cells within the inflammatory infiltrate. These patients have circulating autoantibodies that bind to: (1) the dermal side of salt-split human skin; and (2) a 200 kDa protein in immunoblots of human dermal extracts. The major target antigen, detected by ~90% of sera, is laminin γ1 (see Table 30.1); additional

Downloaded for Anonymous User (n/a) at Egyptian Knowledge Bank from ClinicalKey.com by Elsevier on March 10, 2024. For personal use only. No other uses without permission. Copyright ©2024. Elsevier Inc. All rights reserved.

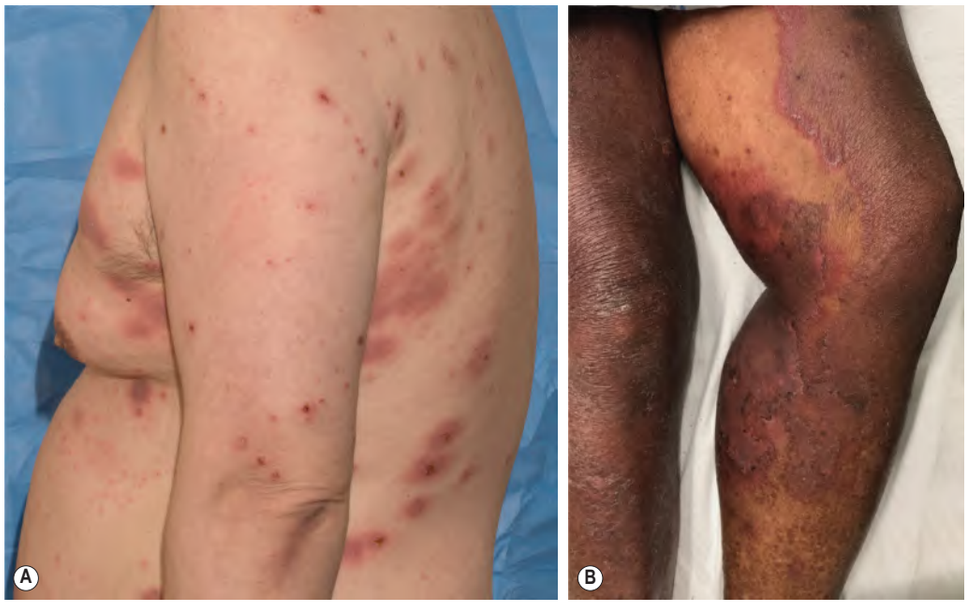

Fig. 30.9 Drug-induced bullous pemphigoid. **A** Scattered pruritic urticarial papules and plaques, some of which have a central hemorrhagic crust, in a patient receiving nivolumab, an anti-PD-1 antibody. **B** Dull violet-brown plaques with a thin inflammatory figurate border and crusting in a patient receiving furosemide. *A, Courtesy Edward Cowen, MD; B, Courtesy Jeff Gehlhausen, MD, PhD.*

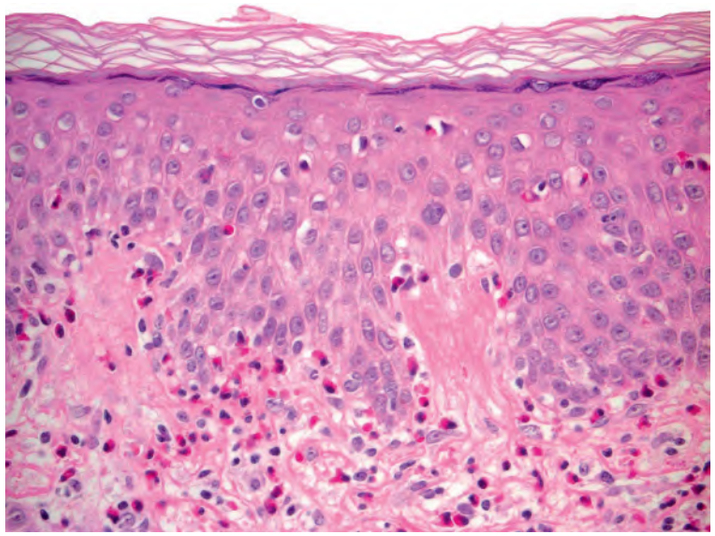

Fig. 30.10 Urticarial phase of bullous pemphigoid – histopathologic features. Eosinophils are present within the dermis as well as the epidermis (eosinophilic spongiosis). Some of the eosinophils have lined up at the dermal–epidermal junction, a typical finding in the urticarial stage of BP. *Courtesy Lorenzo Cerroni, MD.*

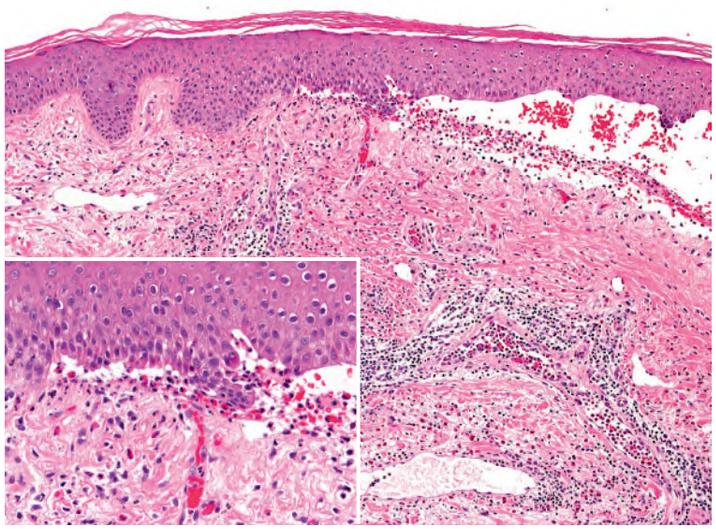

Fig. 30.11 Bullous pemphigoid – histopathologic features. Subepidermal blister which contains fibrin, eosinophils and mononuclear cells (see inset). *Courtesy Lorenzo Cerroni, MD.*

target antigens, which may be pathologically important, have also been identified[20,34]. Of note, anti-p200 pemphigoid and psoriasis often co-exist, especially in Japanese patients.

- **Mucous membrane pemphigoid (MMP)** is a heterogeneous group of diseases which have in common the predominant involvement of the mucosae, a chronic course, and a scarring tendency (see below)[20]. Skin lesions occur in up to 30% of patients and favor the head and upper trunk. When there is both mucosal and cutaneous involvement, distinction from BP may be difficult, but a predominance of mucosal lesions with a scarring tendency and limited skin involvement point to MMP.
- **Chronic pruritic dermatoses of the elderly and early-stage BP**. In the elderly, pruritus, alone or in combination with nonspecific skin lesions, is a common complaint. There are myriad underlying causes and a thorough assessment is often required (see Ch. 6). A dilemma arises when patients with pruritus have circulating autoantibodies to the epidermal BMZ and reactivity with BP180 and/or BP230, but routine DIF microscopy remains negative[18,35]. A small minority of these patients, with initially negative DIF microscopy findings, eventually develop BP[18]. With few exceptions, DIF remains a more definitive diagnostic test than either IIF or ELISA[22].

Prognosis

BP is a chronic disease characterized by spontaneous exacerbations. Approximately 30% of BP patients have a relapse during their first year of treatment, with extensive disease and associated dementia representing independent risk factors for relapse. Furthermore, after cessation of therapy, ~50% of patients experience a relapse, most often within the first 3 months[18,36].

Mortality is considerable among elderly patients. The estimated death rate during the first year varies between 10% and 40%, depending on the series[6,18,20,36]. Older age, dementia, history of a cerebrovascular accident (CVA), and low Karnofsky score have a negative impact on survival[6,36]. The use of systemic corticosteroids or immunosuppressive drugs is also likely to influence overall mortality. Impaired quality of life is obviously an issue for many patients given the associated symptoms[21,22].

Monitoring

The practicality of using the results of quantitative serologic tests, such as ELISA-BP180 or perhaps distinct inflammatory biomarkers[13], as a means of guiding treatment remains to be established. That said, serum

Downloaded for Anonymous User (n/a) at Egyptian Knowledge Bank from ClinicalKey.com by Elsevier on March 10, 2024. For personal use only. No other uses without permission. Copyright ©2024. Elsevier Inc. All rights reserved.

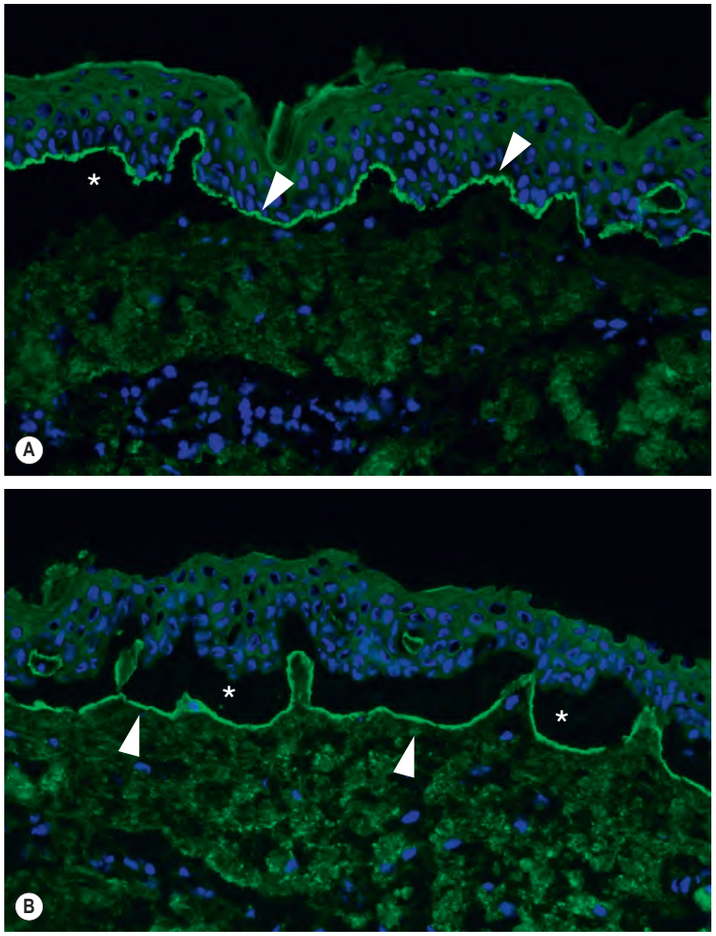

Fig. 30.12 Indirect immunofluorescence (IIF) microscopy utilizing salt-split human skin. A Circulating IgG autoantibodies from BP patients bind to the epidermal side (roof) of the salt-induced split (arrows); the artificial separation is indicated by an asterisk. **B** IgG autoantibodies from patients with EBA, anti-p200 pemphigoid (anti-laminin γ1 pemphigoid), and certain forms of mucous membrane pemphigoid (e.g. with antibodies against laminin 332) react with the dermal side (floor) of the blister (arrows). *Courtesy H. Pas, MD.*

levels of IgG autoantibodies to BP180 correlated with disease severity in several ELISA-based studies[8,9,20,36]. Furthermore, determination of anti-BP180 IgG antibody levels by ELISA at days 0, 60, and 150 appeared to help predict disease relapse – a small (<20%) decrease in serum autoantibody levels between days 0 and 60 was associated with relapse during the first year of therapy[35]. Finally, a high BP180–NC16A ELISA score (>27 U/ml) and, to a lesser degree, positive DIF findings at cessation of therapy are both good indicators of future relapse of BP.

As noted previously, the extent and degree of disease activity can be assessed by employing the BP disease area index (BPDAI)[21] or a daily blister count.

Treatment

The choice of treatment depends on the severity of the disease and comorbidities (Tables 30.3 and 30.4)[22,37–47]. For **extensive** disease, often defined as >10 new blisters/day or inflammatory lesions involving large areas or multiple body sites, either systemic or widespread ultrapotent corticosteroids are employed. *Oral prednisone* (0.5–0.75 mg/kg/day; 1 mg/kg may result in significant side effects and increased mortality) usually controls the disease within 1–2 weeks. If there are no new lesions or pruritus for at least 2 weeks[22,39], then the dosage is progressively tapered to a low dose over a period of 4–6 months, or occasionally longer. Low-dose prednisone is then continued for an additional 3–6 months[22]. Rarely, pulse therapy with methylprednisolone is required for rapid control of the disease. In controlled trials, *ultrapotent topical corticosteroids*, e.g. clobetasol propionate 0.05% cream, had the same efficacy as oral corticosteroids, with fewer systemic side effects and reduced mortality[22,41]. Two topical regimens have been described: standard and mild, in which the starting doses are clobetasol 40 g/day and clobetasol 10–30 g/day, respectively (see Table 30.3)[41]. While ultrapotent topical corticosteroids can be tried first, cost, compliance, and ease of application in the elderly may be limiting factors.

Immunosuppressive therapies can serve as *steroid-sparing agents* and are employed when corticosteroids alone fail to control the disease, there are contraindications to the use of systemic corticosteroids, and/or comorbidities exist that limit the dosage of corticosteroid (e.g. diabetes mellitus, osteoporosis, psychosis)[22]. The most frequently employed agents are azathioprine, mycophenolate mofetil (1.5–3 g/day), methotrexate (7.5–15 mg/week), and cyclophosphamide (see Table 30.4). The dosage of azathioprine (0.5–2.5 mg/kg/day) should be adjusted according to the level of thiopurine methyltransferase, in order to increase efficacy and reduce myelosuppression (see Ch. 130). In the elderly, the dose of methotrexate requires careful monitoring as renal function is often

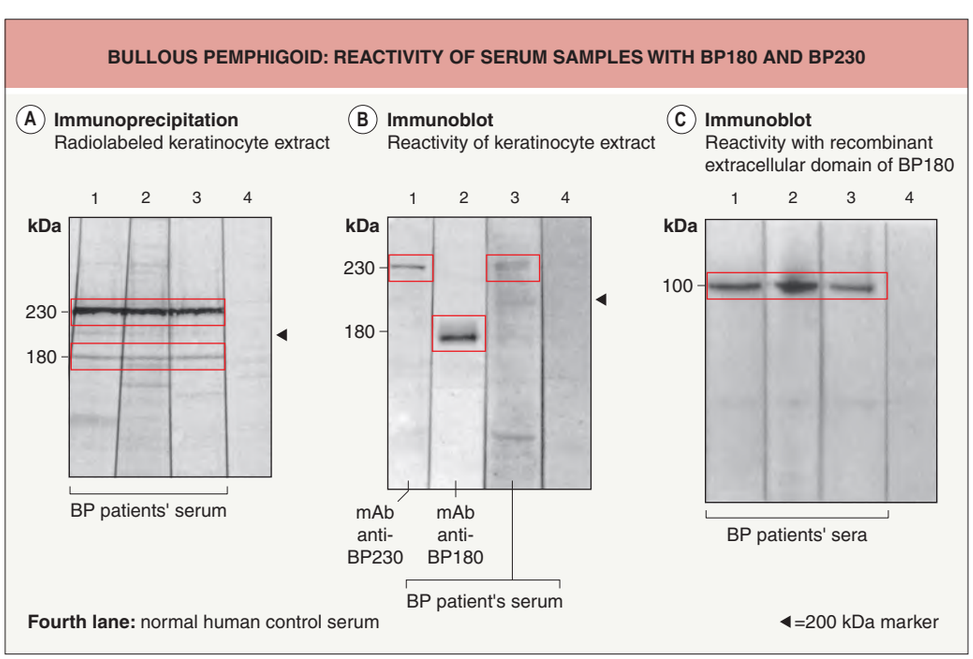

Fig. 30.13 Bullous pemphigoid (BP): reactivity of serum samples with BP180 and BP230. A Immunoprecipitation studies utilizing radiolabeled human keratinocyte extracts: lanes 1–3, serum samples from BP patients immunoprecipitate proteins of 230 kDa (BP230) and 180 kDa (BP180); lane 4, reactivity of normal human serum. **B** Immunoblot studies of keratinocyte extracts: lane 1, reactivity of monoclonal antibodies directed against BP230; lane 2, reactivity of monoclonal antibodies directed against BP180; lane 3, reactivity of a BP serum sample with a protein of approximately 230 kDa; lane 4, reactivity of normal human serum. **C** Reactivity with the extracellular domain of BP180, which was expressed by transfection of COS-7 cells: lanes 1–3, serum samples from BP patients; lane 4, normal human serum.

Downloaded for Anonymous User (n/a) at Egyptian Knowledge Bank from ClinicalKey.com by Elsevier on March 10, 2024. For personal use only. No other uses without permission. Copyright ©2024. Elsevier Inc. All rights reserved.

SURVEY OF SELECTED CONTROLLED TRIALS FOR THE TREATMENT OF PATIENTS WITH BULLOUS PEMPHIGOID						
Authors (year)	Trial design	Intervention		Number of patients	Response	Remarks
Guillaume et al.[37] (1993)	Randomized, multicenter	Group 1	Prednisolone (1 mg/kg/day) alone	98	At month 6, no significant difference in remission rate between group 1 (42%), group 2 (39%), and group 3 (29%)	More complications in group 2 No adjustment of doses of azathioprine based on TPMT levels
		Group 2	Prednisolone plus azathioprine (100–150 mg/day)			
		Group 3	Prednisolone plus 4 plasma exchanges			
Joly et al.[39] (2002)	Randomized, multicenter	Group 1	Topical clobetasol propionate	341	At week 3, control rates better in group 1	At year 1, topical therapy was associated with a significantly reduced mortality and complication rate
		Group 2	Prednisone (0.5–1 mg/kg/day)			
Beissert et al.[40] (2007)	Randomized, multicenter, prospective	Group 1	Methylprednisolone (0.5 mg/kg/day) plus azathioprine (2 mg/kg/day)	38	Disease control similar in the two groups	In group 1, higher incidence and severity of liver toxicity Trend for faster disease control and less total cumulative doses of corticosteroids in group 1 No adjustment of doses of azathioprine based on TPMT levels
		Group 2	Methylprednisolone (0.5 mg/kg/day) plus mycophenolate mofetil (2 g daily)	35		
Joly et al.[41] (2009)	Randomized, multicenter, prospective	Group 1	Topical clobetasol propionate *standard* regimen for 12 months (40 g daily as starting dose)	153	Time to achieve disease control similar in both groups At 1 year, trend for higher relapse rate in patients with moderate BP treated with *mild* regimen	In moderate BP treated with *mild* regimen, decrease in side effects and death Lower cumulative dose of clobetasol in *mild* regimen
		Group 2	Topical clobetasol propionate, *mild* regimen for 6 months (10–30 g daily as starting dose)	159		
Williams et al.[42] (2017)	"Pragmatic" parallel-group, randomized, multicenter, prospective	Group 1	Doxycycline (200 mg/day); localized adjuvant potent topical corticosteroids permitted during first three weeks After 6 weeks, possible switch to group 2	132	At week 6, proportion of participants with ≤3 blisters is lower in group 2 (adjusted difference favors prednisolone) At one year, severe and fatal events appear to be lower in group 1	Per authors, doxycycline noninferior for short-term blister control and better long-term safety profile Limitations include study design with possible switch in treatment and use of topical corticosteroids by some participants
		Group 2	Prednisolone (0.5 mg/kg per day) After 6 weeks, possible switch to the other therapy or adjustment of prednisolone dose	121		
Amagai[43] (2017)	Randomized, double-blind multicenter	Group 1	Add-on therapy with IVIg (2 g/kg/day) in patients with no improvement on prednisolone ≥0.4 mg/kg/day	29	Trend towards better responses in group 1 during the observation period (days 15 and 56 were time points)	Primary endpoint did not reach statistical significance (but *post-hoc* analysis of covariance demonstrated clinical significance) Compared to placebo, IVIg improved severe disease and increases in prednisolone dose not required
		Group 2	Placebo as add-on therapy in patients with no improvement on prednisolone ≥0.4 mg/kg/day	27		
Simon et al.[44] (2019)	Randomized, placebo-controlled, double-blind, single institution	Group 1	Mepolizumab (750 mg every 4 weeks for 12 weeks) in addition to standard of care: prednisolone (0.5 mg/kg/day) with discontinuation of prednisolone within 12 weeks	20	Group 1 regimen (i.e. add-on mepolizumab) did not significantly affect clinical outcome at weeks 16 and 36	For patients on prednisolone, mepolizumab did not significantly impact disease control or relapse rate compared to placebo Significantly lower number of circulating eosinophils in group 1, but no difference in tissue eosinophils Inclusion of few patients with severe disease could obscure effect of mepolizumab
		Group 2	Placebo every 4 weeks for 12 weeks in addition to standard of care with prednisolone (see group 1)	10		

Table 30.3 Survey of selected controlled trials for the treatment of patients with bullous pemphigoid. TPMT, thiopurine methyltransferase.

significantly reduced. The choice of a particular immunosuppressive drug depends on its side-effect profile, the patient's overall condition, and the experience of the physician.

For **localized** involvement or mild disease with a limited number of non-bullous inflammatory lesions, potent topical corticosteroids represent first-line therapy[21]. Tetracycline, doxycycline or minocycline, alone or in combination with nicotinamide (500–2000 mg/day), can lead to clinical improvement and may be considered as a therapeutic alternative when contraindications to corticosteroids exist[22,38]. A trial comparing doxycycline with prednisolone reported acceptable blister control and a better safety profile with doxycyline, but the latter often needed to be combined with corticosteroids during the course of the disease[42]. Unless there is glucose-6-phosphate dehydrogenase deficiency, the use of dapsone may also be warranted, particularly in the presence of mucosal involvement; topical immunomodulators (e.g. tacrolimus) are an additional option.

Downloaded for Anonymous User (n/a) at Egyptian Knowledge Bank from ClinicalKey.com by Elsevier on March 10, 2024. For personal use only. No other uses without permission. Copyright ©2024. Elsevier Inc. All rights reserved.

THERAPEUTIC LADDER FOR BULLOUS PEMPHIGOID
Mild and/or localized disease
First-line
• Superpotent topical corticosteroids (1*) • Oral corticosteroids† (1) • Minocycline, doxycycline or tetracycline, alone or in combination with nicotinamide (1)
Second-line
• Topical immunomodulators (e.g. tacrolimus) (3) • Dapsone, sulfonamides (3) • Erythromycin, penicillins (3)
Extensive/persistent cutaneous disease
First-line, as primary treatment
• Superpotent topical corticosteroids (1*) • Oral corticosteroids† (1‡)
Second-line, or as adjunctive therapy
• Azathioprine (1) • Mycophenolate mofetil (1) • Methotrexate¶ (2) • Omalizumab (3) • Dupilumab (3) • IVIg (1) • Rituximab (3) • Cyclophosphamide (3) • Immunoadsorption (3)
Note: Superpotent topical corticosteroids should be considered in any patient and may be combined with a systemic therapy.
*Validated. †Prednisone doses of at least 0.5–0.75 mg/kg/day seem to be necessary to control extensive disease, with increased side effects and mortality at 1 mg/kg. For mild to moderate disease, 0.5 mg/kg/day is sufficient. ‡Validated for prednisone. ¶In elderly patients, low-dose regimen (2.5–10 mg/week) can be effective.

Table 30.4 Therapeutic ladder for bullous pemphigoid. Key to evidence-based support: (1) prospective controlled trial; (2) retrospective study or large case series; (3) small case series or individual case reports.

In case series, both dupilumab and omalizumab have been used as monotherapy or as steroid-sparing agents with favorable responses and safety profiles (see Ch. 128)[45,46]. The pathogenic roles of IL-4 and IL-13 signaling pathways as well as IgE autoantibodies suggest that they are potential therapeutic targets in BP. In treatment-resistant cases, anti-CD20 immunotherapy (rituximab)[47] and IVIg can also be considered. Therapies under investigation include inhibitors of IL-17, IL-12/-23, IL-5Rα, eotaxin, and complement molecules (e.g. C5aR).

While the optimal duration of therapy has not been established, BP patients usually need to be treated for a range of 9–12 months, depending upon the severity of the disease and therapeutic response. The exception is steroid-resistant or steroid-dependent disease. This time period includes a maintenance phase in which low-dose oral prednisone (<10 mg/day) or topical clobetasol propionate (10 g/week) is continued for 1 to 6 months after cessation of clinically active disease[25]. Finally, in all patients with BP, it is important to minimize the complications of both the cutaneous lesions and the systemic treatment, including using osteoporosis prophylaxis and gastric protection (see Ch. 125).

MUCOUS MEMBRANE PEMPHIGOID

Synonyms (becoming historical): ■ Cicatricial pemphigoid ■ Benign mucous membrane pemphigoid

Subtypes/variants: ■ Anti-laminin 332 (mucous membrane) pemphigoid – anti-epiligrin cicatricial pemphigoid ■ Brunsting–Perry pemphigoid

Key features

- Mucous membrane pemphigoid is a chronic, autoimmune, subepithelial blistering disorder characterized by predominant involvement of the external mucosal surfaces and a tendency for scarring
- It is associated with tissue-bound and, less often, serum autoantibodies directed against distinct structural components of basement membranes in stratified and some complex epithelia: BP180, BP230, laminin 332 (laminin 5), type VII collagen, and likely integrin β_4 and α_6 subunits
- The condition should not be regarded as a clinical entity, but as a "disease phenotype" shared by a heterogeneous group of diseases with lesions that favor the mucosal surfaces and, less frequently, the skin
- As scarring frequently affects the conjunctivae, the disorder can be devastating and ultimately lead to blindness
- Diagnosis relies on immunopathologic examinations, especially DIF microscopy, and serological immunoassays

Introduction

Mucous membrane pemphigoid (MMP) is a rare autoimmune subepithelial blistering disorder characterized by predominant involvement of the mucosae, a chronic course, and a tendency towards scarring of the affected areas. The disorder should not be regarded as a clinical entity, but rather as a "disease phenotype" shared by a heterogeneous group of blistering diseases, with predilection for the mucosal surfaces[48]. The majority of patients have linear deposits of immunoglobulins and/or complement components along the epithelial BMZ of the skin and mucosae. Circulating anti-BMZ autoantibodies are detected in the serum of some patients (20%–30% by standard IIF), usually at a low titer or concentration. It is a chronic and progressive disease, which may result in serious mucosal complications. When postinflammatory atrophy or scarring affect the conjunctivae, the disorder can be devastating and ultimately lead to blindness.

History

In 1794, Wichmann first described a chronic blistering disease associated with involvement of the eyes. Civatte separated this disorder from pemphigus on the basis of peculiar histopathologic findings in 1949, and Lever later suggested the name "benign mucous membrane pemphigoid", a misnomer in view of the potentially severe complications of the disorder. During the latter part of the 20th century, the term "cicatricial pemphigoid" was used primarily. In 2012, based upon an international consensus conference, the term "mucous membrane pemphigoid" was proposed. Demonstration of immunoreactants deposited along the epithelial BMZ by IF microscopy pointed to an autoimmune origin.

Epidemiology

The annual incidence of MMP is ~1 to 2 cases per million population[49], with a calculated prevalence (in Germany) of 25 cases per million inhabitants. MMP typically occurs in the elderly, with a mean age at the time of diagnosis of between 60 and 80 years. However, isolated cases have been reported in children. Women are affected more frequently than men (estimated ratio 1.5–2:1). Although no geographic or racial predilection has been described, several studies have shown an association with specific immunogenetic HLA class II haplotypes, e.g. HLA-DQw7 (subtype HLA-DQB1*03:01), in both oral and ocular forms of the disease[50]. There is no overall association with malignancy, but in a distinct subtype associated with IgG autoantibodies directed against laminin 332 (also known as anti-epiligrin cicatricial pemphigoid), an increased relative risk for cancer has been suggested[48,51]. Although this is debated, a search of an associated solid tumor may be recommended in case of anti-laminin 332 reactivity.[48] For example, in a retrospective study of 154 patients, an association of anti-laminin 332 reactivity with malignant neoplasms was noted, with an adjusted odds ratio of 23[50a]. Recently, MMP has been observed in patients receiving immune checkpoint inhibitors.

Downloaded for Anonymous User (n/a) at Egyptian Knowledge Bank from ClinicalKey.com by Elsevier on March 10, 2024. For personal use only. No other uses without permission. Copyright ©2024. Elsevier Inc. All rights reserved.

Pathogenesis

Mucocutaneous lesions are thought to result from the binding of autoantibodies to the BMZ of stratified epithelia of mucosae and skin. These autoantibodies recognize distinct structural components of the hemidesmosomal adhesion complex. Specifically, they appear to bind predominantly to antigenic sites located extracellularly within the anchoring filament zone rather than within the hemidesmosomal plaque[52]. However, the pathogenicity of various IgG autoantibodies associated with this disease phenotype (see Table 30.1) has not yet been established unequivocally and other mechanisms may also be involved. In a minority of patients with MMP, BP180–NC16A domain-specific T cells are detectable. Increased expression of collagen-binding heat shock protein 47 (HSP47) and TGF-β1 by conjunctival fibroblasts may contribute to the conjunctival scarring seen in patients with ocular disease[53].

Based upon their autoantibody profile, patients with MMP can be divided into four distinct subgroups. The **first** subgroup includes those with autoantibodies directed against laminin 332. This subgroup was previously referred to as *anti-laminin 332 MMP* or anti-epiligrin cicatricial pemphigoid[54]. It is estimated that 18%–30% of patients with MMP belong to this subgroup[55]. Patients with anti-laminin 332 IgG autoantibodies frequently have multiple sites of mucosal involvement, including the pharynx, larynx, and trachea[48]. Their circulating IgG autoantibodies bind to the dermal side of salt-split skin and react with the α_3 chain (G domain) and, less frequently, the β_3 and/or γ_2 chain of laminin 332 ($\alpha_3\beta_3\gamma_2$) (see Fig. 28.5). Occasionally, antibody binding to the α_3 chain of laminin 311 (previously termed laminin 6 [a heterotrimer of $\alpha_3\beta_1\gamma_1$ chains]) is also observed because of the presence of cross-reacting autoantibodies. *In vitro* and *in vivo* studies have provided convincing evidence that autoantibodies to laminin 332 are pathogenic[55].

In the **second** group of patients, involvement is exclusively or predominantly ocular. IgG autoantibodies that bind to the β_4 subunit of $\alpha_6\beta_4$ integrin, a transmembrane hemidesmosomal component that interacts with laminin 332, have been described anecdotally. Some clinicians refer to this subset as *ocular MMP* (see Fig. 28.3A)[56].

A **third** subgroup of patients, who lack a specific clinical phenotype, have tissue-bound and circulating IgG antibodies that react with the same target antigens as in BP, especially BP180. These patients, who have been classified as having *anti-BP antigen MMP*, represent the largest subgroup. The antigenic regions targeted on BP180 are located within the NC16A domain and on its distal COOH-terminal portion. The latter appears to extend into the lamina densa region of the BMZ (see Fig. 28.3A)[52]. There is ample scientific evidence that anti-BP180 IgG antibodies are pathogenic[11].

The **fourth** group is rather heterogeneous. It includes patients who have variable involvement of the mucosae without involvement of the skin. While it is yet unclear whether injury occurs as a result of an autoantibody-mediated immune response against proteins of the BMZ, a few patients with an MMP phenotype have shown reactivity against type VII collagen. It has been reported that a small subset of patients with oral MMP have autoantibodies which bind to the α_6 subunit of $\alpha_6\beta_4$ integrin, but this needs to be validated[57].

Clinical Features

Mucous membranes

The two most frequently involved sites in patients with the "mucous membrane pemphigoid phenotype" are the oral and conjunctival mucosae. However, the disease may also start in, and affect, any mucosal site, including the nasopharyngeal, anogenital, laryngeal, or esophageal mucosa (in descending order of frequency)[48,58–60].

Approximately 90% of patients have oral involvement (often in the absence of skin lesions), and the oral cavity may be the only site of disease activity in up to 30% of patients. Lesions frequently involve the gingiva, buccal mucosa, and palate; the alveolar ridges, tongue, and lips are less commonly affected. A classic oral presentation is desquamative gingivitis accompanied by bleeding erosions and paresthesias (Fig. 30.14A); small intact blisters are rarely observed. Chronic inflammation may lead to periodontal ligament damage and the loss of teeth. In other areas of the mouth, transient vesicles give rise to chronic erosions, especially on the palate (Fig. 30.14B), with variable associated pain. Lesions on the tongue are usually localized to its lateral and ventral surfaces. Adhesions may develop in the area of the uvula and tonsillar fossae as well as between the tongue and the floor of the mouth. White, reticulated striations that resemble oral lichen planus may also be seen.

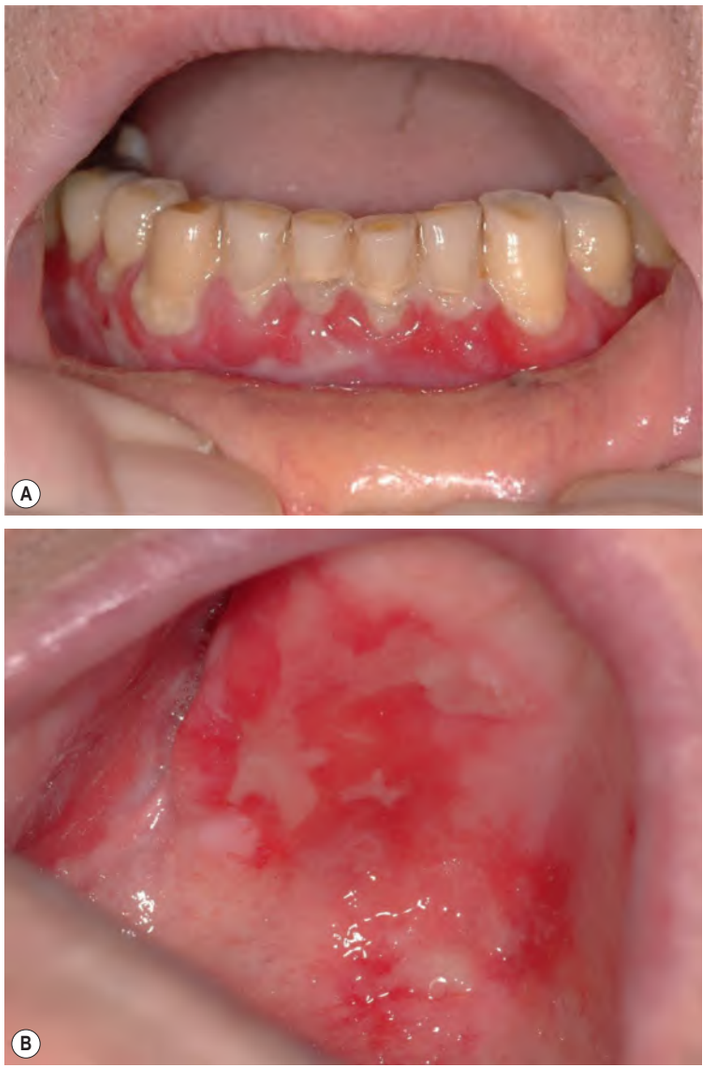

Fig. 30.14 Mucous membrane pemphigoid. A Desquamative gingivitis with erythema and erosions of the gingival margins. Note the sloughing of the mucosa with shaggy margins. **B** Chronic erosions on the hard palate with irregular borders. Sloughing of mucosa is seen superiorly.

Conjunctival involvement occurs in ~40% of patients[48,54] and can result in blindness[60]. The conjunctivae are frequently the only site affected. Although the disease may begin unilaterally, in the majority of patients, lesions appear in both eyes. Ocular involvement starts as a nonspecific chronic conjunctivitis and limbitis, with burning, soreness, foreign-body sensation, decreased vision, and/or mucus production. Periods of exacerbations and subsequent remissions are typical, with eventual progression to a scarring due to subepithelial conjunctival fibrosis (Fig. 30.15).

Conjunctival vesicles or blisters are rare on the tarsal conjunctiva. Chronic inflammation may result in progressive scar tissue formation, leading to a shortened inferior fornix and symblepharon (an adhesion between bulbar and palpebral conjunctival surfaces; Fig. 30.16) as well as ankyloblepharon. Conjunctival fibrosis can also result in trichiasis (inwardly angled eyelashes) and entropion[60]. In uncontrolled disease, trichiasis, entropion, and xerosis (due to scarring of the lacrimal ducts) eventuate in superficial corneal trauma, corneal neovascularization with subsequent corneal ulceration, and blindness[48].

Nasopharyngeal involvement occurs in a third of patients with MMP and is typically chronic and asymptomatic[48,59]. It results in crusted intranasal ulcerations, epistaxis, fibrous adhesions between adjacent mucosal surfaces, and airway obstruction. Pharyngeal involvement presents as ulcerations of the posterior or lateral pharynx and dysphagia. Laryngeal involvement is a potentially serious manifestation, presenting as hoarseness, loss of speech, and even life-threatening stenosis, which requires tracheostomy.

Although esophageal disease may be accompanied by dysphagia resulting from erosions of the esophageal mucosa, involvement can be

Downloaded for Anonymous User (n/a) at Egyptian Knowledge Bank from ClinicalKey.com by Elsevier on March 10, 2024. For personal use only. No other uses without permission. Copyright ©2024. Elsevier Inc. All rights reserved.

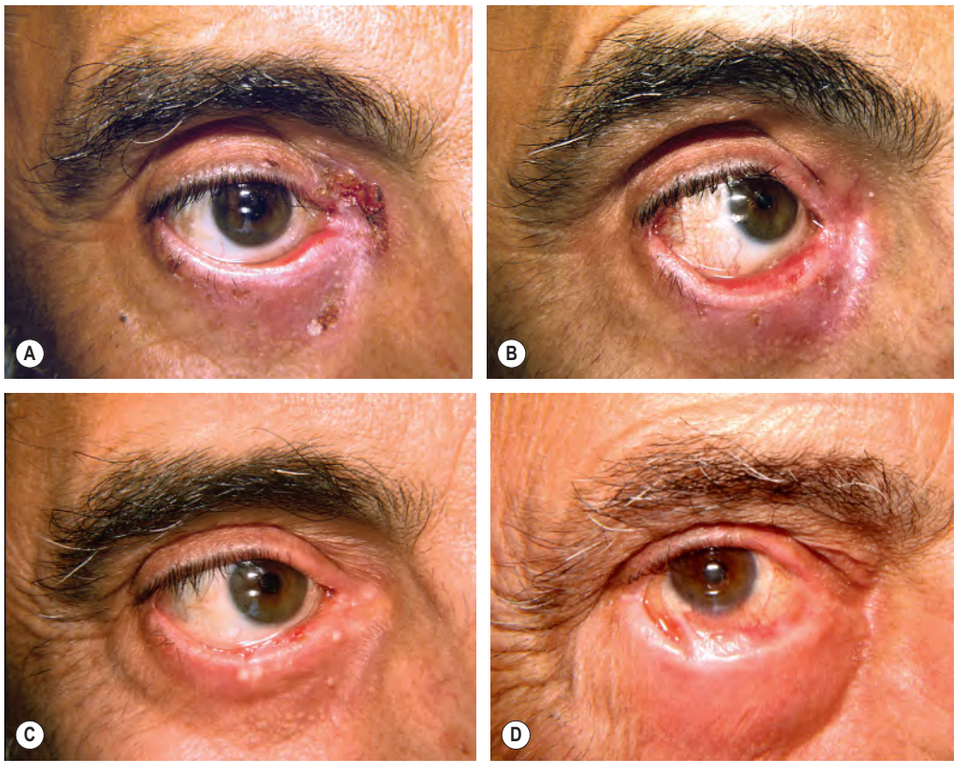

Fig. 30.15 Ocular involvement in mucous membrane pemphigoid. A Erosion and erythema of the lower medial eyelid margin plus scale-crust of the inner canthus and lower eyelid. **B** Three months later, ectropion and thickening of the lower eyelid in addition to erosions. **C** Six months later, smaller erosions but scarring and milia formation. **D** Seven years later, further scarring with significant shortening of the inferior fornix due to symblepharon. *Courtesy Louis A. Fragola, Jr, MD.*

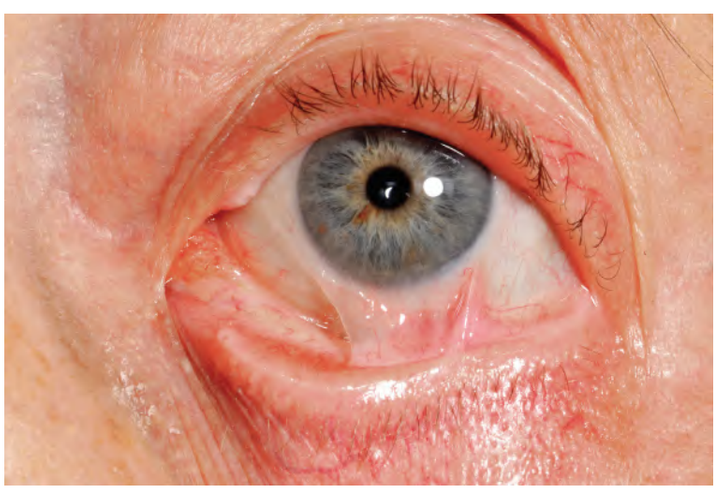

Fig. 30.16 Mucous membrane pemphigoid. Typical ocular involvement as manifested by fibrous tracts, representing partial or incomplete symblepharon.

entirely asymptomatic. Chronic inflammation can lead to strictures and stenosis, with associated dysphagia[48].

Involvement of genital and anal mucosae is relatively uncommon, but increasingly recognized. Early lesions consist of blisters and chronic erosions. In female patients, progressive disease leads to scarring and narrowing of the introitus. In male patients, adhesions can form between the prepuce and the glans penis. Anal involvement can also lead to scarring and, in severe cases, to stricture formation[48].

Cutaneous lesions

The skin is involved in 20%–35% of patients. The most frequently involved sites are the scalp, face, neck, and upper trunk. Lesions typically present as erythematous plaques, which become sites for recurrent blister formation and erosions, with subsequent scarring. Their extent and number are generally limited, but an individual patient can have a BP-like clinical presentation[48].

In the *Brunsting–Perry variant*, skin lesions are localized predominantly to the head and neck and upper trunk (Fig. 30.17A,B)[61]. Mucosal involvement is usually absent or minimal. On the scalp, significant scarring alopecia can result (Fig. 30.17C).

Diagnosis and Differential Diagnosis

The diagnosis of MMP has to be considered in all patients who have blistering or erosive lesions that predominantly involve mucous membranes and whose affected tissues show linear, continuous deposits of immunoreactants along the epithelial BMZ. Unfortunately, there is frequently a significant delay, often more than a year, before the diagnosis is established. As a result, moderate to severe scarring, especially ocular, may have already occurred.

Light microscopy and electron microscopy

The histopathologic features of MMP and BP are often similar. Examination of a fresh vesicle or bulla demonstrates subepithelial or subepidermal blister formation (without acantholysis). A mixed cellular infiltrate of variable intensity is present, with a predominance of neutrophils; the number of eosinophils is increased in older lesions, but they are still fewer than in BP. Older lesions also tend to have scarring in the submucosa or upper dermis. In oral lesions, the inflammatory infiltrate typically contains some plasma cells, a nonspecific finding related to the mouth being a mucosal site. The epithelium of affected conjunctivae is often invaded by inflammatory cells, including mononuclear cells and mast cells, while granulation tissue is found in the submucosa.

In most cases, electron microscopy studies of a fresh blister demonstrate that the dermal–epidermal cleavage occurs within the lamina lucida. In advanced conjunctival lesions with scarring, the lamina densa appears to be discontinuous, focally thickened, or duplicated.

Direct immunofluorescence (DIF) microscopy

By DIF microscopy, 80%–95% of patients with MMP have *in vivo* bound autoantibodies directed against the BMZ of mucosae and/or skin. The majority of patients exhibit continuous, fine, linear deposits of IgG, IgA, and/or C3 along the epithelial BMZ in perilesional biopsy specimens. It should be noted that DIF microscopy studies of mucosae are more frequently positive (50%–90%) than those of skin (20%–50%). IgG deposits belong primarily to the IgG4 and IgG1 subclasses; deposits of IgM and fibrin are less common. DIF microscopy of salt-split skin is of less diagnostic value. Although a combined pattern with staining of both the epidermal and dermal sides is frequently observed, reactivity with either the epidermal roof or the dermal floor of the separated skin is occasionally noted. If circulating autoantibodies are not detected, analysis of the

Downloaded for Anonymous User (n/a) at Egyptian Knowledge Bank from ClinicalKey.com by Elsevier on March 10, 2024. For personal use only. No other uses without permission. Copyright ©2024. Elsevier Inc. All rights reserved.

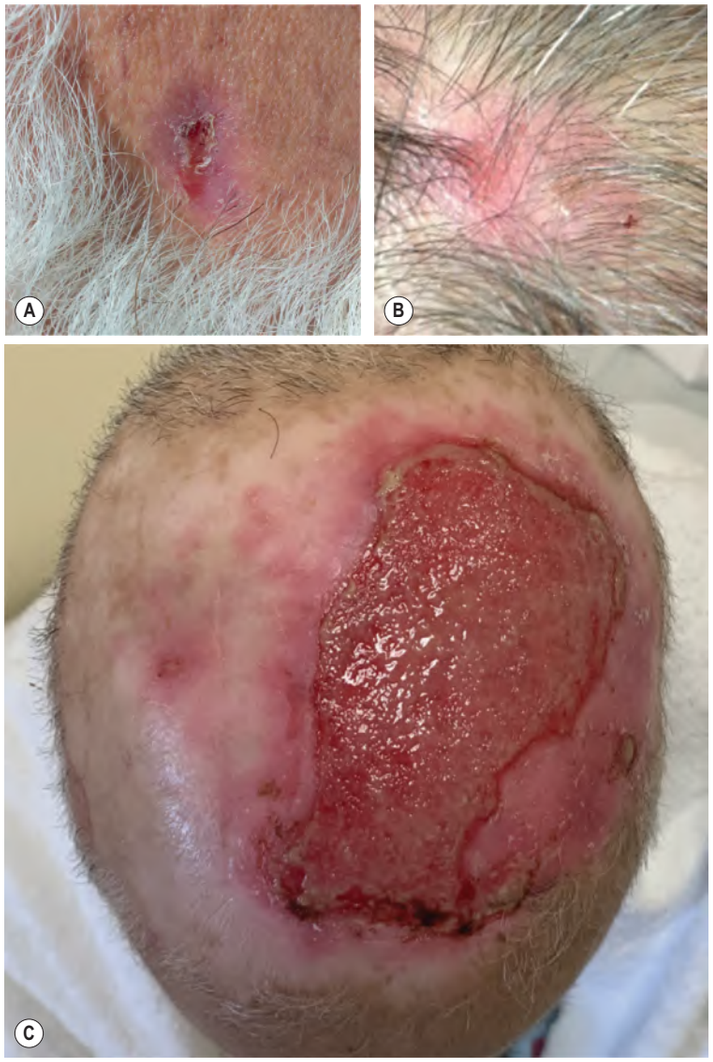

Fig. 30.17 Mucous membrane pemphigoid – Brunsting–Perry variant. A Crusted erosion on the lower cheek within an oval area of inflammation and scar. **B** Mild involvement of the scalp with scarring and atrophy resulting in limited alopecia. **C** Severe involvement of the scalp with an ulceration within a large area of scarring alopecia. *B, Courtesy Karynne O. Duncan, MD; C, Courtesy Michael Gowen, MD.*

linear fluorescence pattern of autoantibody deposits at the cutaneous BMZ (*n-serrated* [pemphigoid group] versus *u-serrated* [EBA]) or results of the FOAM technique (see above) may prove helpful. Of note, in mucosal specimens, the serration pattern cannot be assessed[48].

Immunoelectron microscopy

Although electron microscopy studies are not routinely available and are time-consuming, they may be particularly useful in establishing the diagnosis of MMP, especially in patients in whom standard DIF and IIF microscopic findings are negative. Direct immunoelectron microscopy studies in MMP have demonstrated immune deposits distributed either: (1) in the lower lamina lucida and above the lamina densa; or (2) on and around hemidesmosomes, with most of the labeling on the outside of basal keratinocytes below their plasma membranes[48,52].

Indirect immunofluorescence (IIF) microscopy

By standard IIF, anti-BMZ autoantibodies can be detected in serum samples from 20%–30% of patients with MMP. Antibodies are mainly of the IgG class, but circulating IgA or IgE may also be detected. Antibody concentrations are usually very low. Some authors have suggested that patients with high serum levels of IgG and IgA anti-BMZ autoantibodies have more severe disease[62]. The sensitivity of IIF can be increased either by the use of normal oral or genital mucosa and conjunctiva as substrates, or by utilizing salt-split skin. Using this latter technique, most patients with MMP have antibodies that bind to the epidermal roof, whereas MMP patients with anti-laminin 332 or anti-type VII collagen reactivity have IgG antibodies that bind to the dermal side (see Fig. 30.12). The use of salt-split oral mucosa does not improve the overall sensitivity. Distinguishing MMP with anti-laminin 332 autoantibodies from EBA may be possible by IIF microscopy using "knockout" skin substrates, i.e. substrates deficient in specific basement membrane proteins[63].

Immunochemical studies, including ELISA

Immunochemical techniques, including ELISA, immunoblots, and immunoprecipitation, have confirmed that the autoantigens targeted in patients with a MMP phenotype are heterogeneous[54,55,57,63–67]. Serum autoantibodies react with various proteins located within the epithelial BMZ, e.g. BP180, laminin 332, type VII collagen (see Table 30.1). Depending upon the patient population and specific assay, IgG anti-BP180 or anti-laminin 332 antibodies are detected in 30–70% or 15–30% of MMP patients, respectively. These targeted antigens appear to constitute serologic markers for different subgroups of MMP (see above).

Patients may have IgA autoantibodies directed against the ectodomain of BP180[6]. As a result, salivary IgG and IgA autoantibodies directed against BP180–NC16A may serve as diagnostic biomarkers. In some cases, these autoantibodies appear to preferentially bind to antigenic reactive sites present on the proteolytically cleaved and shed portion of the extracellular domain of BP180, i.e. the LABD antigen (LAD-1; see Ch. 31). Lastly, several unidentified target antigens of varying molecular weights have also been reported.

ELISAs that utilize recombinant proteins or affinity-purified native proteins (e.g. BP180, laminin 332, type VII collagen) can be useful in the search for circulating autoantibodies[31].

Differential diagnosis

Distinction from other subepidermal autoimmune bullous diseases (including BP, EBA, and LABD) may be difficult and often relies on the predominance of mucosal involvement and chronic course. In contrast, pemphigus vulgaris and non-autoimmune blistering diseases are more easily excluded via histology and IF microscopy.

If oral involvement, especially isolated desquamative gingivitis, is the sole manifestation of MMP, it can be difficult to differentiate clinically from pemphigus vulgaris or erosive lichen planus. End-stage, scarring conjunctival lesions may mimic severe chronic infectious conjunctivitis, ocular pseudopemphigoid due to ophthalmologic preparations (including pilocarpine, idoxuridine, guanethidine, β-blockers), or sequelae of Stevens–Johnson syndrome and toxic epidermal necrolysis. While the rare, generalized cutaneous form of MMP can be impossible to distinguish from BP, involvement of multiple mucosal sites favors the former.

Prognosis

MMP is a particularly chronic, potentially devastating, but rarely fatal disease. The most important complication is impairment of vision due to ocular involvement. It can also lead to weight loss as well as respiratory, sexual, or urinary complications. Even with localized involvement, this disease can have a major negative impact on quality of life. Life-threatening complications, due to severe laryngeal, tracheal or esophageal disease, are rare.

Treatment

Treatment can be difficult and at times frustrating, with therapeutic regimens based primarily on clinical experience[67].

Local therapy is crucial and, for limited involvement, it can be sufficient. Mild to moderate disease activity may be successfully treated with potent topical corticosteroids. Oral lesions can respond to topical corticosteroids (as mouthwashes or topical preparations in a gel or occlusive base supplemented by customized prosthetic devices to provide occlusion) in conjunction with tetracycline mouthwashes and professional dental hygiene. Corticosteroid sprays and inhalers may prove useful in nasal, pharyngeal, or esophageal disease. Recalcitrant lesions of both skin and mucous membranes may improve with intralesional injections of triamcinolone. Esophageal strictures may require dilatations to prevent dysphagia, while severe tracheal involvement may require a tracheostomy to prevent asphyxiation[68].

Systemic medications include dapsone (50–150 mg/day) as a first-line therapy for controlling oral and cutaneous lesions, and it may also

Downloaded for Anonymous User (n/a) at Egyptian Knowledge Bank from ClinicalKey.com by Elsevier on March 10, 2024. For personal use only. No other uses without permission. Copyright ©2024. Elsevier Inc. All rights reserved.

be used for mild ocular disease without rapid worsening. Dapsone can be particularly beneficial in patients with linear deposits of IgA at the BMZ. Cyclophosphamide (1–2 mg/kg/day) is considered the treatment of choice for rapidly progressive or severe ocular disease[60] – alone, in combination with oral corticosteroids, or as pulse therapy. Such regimens are effective in resolving severe conjunctival inflammation and preventing recurrences and secondary scarring. Azathioprine (2 mg/kg/day) and mycophenolate mofetil (2 g/day) have also been reported to be helpful in reducing the dose of corticosteroids required for control of ocular involvement and cutaneous lesions.

Systemic corticosteroids alone are generally insufficient therapy for patients with significant disease, and they are less effective for mucosal than for cutaneous disease. Patients with significant esophageal or laryngotracheal involvement should be treated aggressively with the combination of prednisone and cyclophosphamide or mycophenolate mofetil to prevent potentially life-threatening complications. Other therapies reported to be of potential value in the treatment of MMP include topical tacrolimus, a combination of tetracycline and niacinamide, minocycline, sulfapyridine, methotrexate, TNF inhibitors, IVIg, topical or systemic cyclosporine, thalidomide, and subconjunctival mitomycin[69–73]. Case series have also underscored the efficacy of rituximab in controlling progressive ocular involvement and severe extraocular complications[67,72]. When these manifestations fail to respond to cyclophosphamide plus corticosteroids or there is an intolerance or contraindication to this regimen, rituximab can be considered as second-line therapy[58].

Surgical therapy may occasionally be necessary for severe scarring involving the eye, larynx, esophagus, or genitalia. It should be performed when the disease is fully controlled by medical therapy. For ocular disease, surgical intervention includes corneal grafts, allograft limbal transplantation, amniotic membrane transplantation, and tarsorrhaphy.

EPIDERMOLYSIS BULLOSA ACQUISITA

Synonym: ■ Acquired epidermolysis bullosa; dermolytic pemphigoid

Key features

- Epidermolysis bullosa acquisita is a rare, acquired, subepidermal bullous disease associated with autoimmunity to type VII collagen, the major component of the anchoring fibrils of the dermal–epidermal BMZ
- Patients may present either with a mechanobullous disorder, mimicking dystrophic epidermolysis bullosa, or with clinical features that resemble BP or infrequently MMP, the Brunsting–Perry variant of MMP, or LABD
- Diagnosis relies on immunopathologic examinations, especially immunofluorescence microscopy, immunoserologic studies, and occasionally immunoelectron microscopy
- The disease is usually chronic and more refractory to treatment than BP

Introduction

Epidermolysis bullosa acquisita (EBA) is a rare, acquired, subepidermal bullous disease associated with autoimmunity to type VII collagen, the major component of the anchoring fibrils of the dermal–epidermal BMZ[74–77]. Patients may present with either a non-inflammatory variant, the features of which strikingly resemble those observed in patients with dystrophic epidermolysis bullosa (EB), or with an inflammatory variant that mimics BP. Infrequently, the clinical phenotype resembles MMP, the Brunsting–Perry variant of MMP, or LABD.

History

The first cases of an acquired bullous disease with clinical features mimicking hereditary dystrophic epidermolysis bullosa were described by Elliot in 1895. In the early 1970s, before the advent of cutaneous immunopathology, Roenigk and colleagues proposed the initial clinical criteria for EBA. A few years later, IF microscopy studies demonstrated that EBA patients have anti-BMZ antibodies, similar to BP patients. In the early 1980s, immunoelectron microscopy studies separated EBA from BP by demonstrating that IgG deposits in EBA were located in the sublamina densa region of the BMZ. In the 1990s it was shown that EBA autoantibodies bind to type VII collagen, the major component of anchoring fibrils[75].

Epidemiology

EBA has been reported in both children and adults and may occur at any age. It is one of the rarest subepidermal autoimmune bullous diseases in Western Europe, with an estimated annual incidence of ~0.25 per million people[49,77]. It may be more common in specific Asian populations (e.g. Koreans) as well as in African-Americans.

Pathogenesis

The pathogenic role of autoantibodies to type VII collagen is supported by several lines of evidence[76]. Patients with EBA have tissue-bound and circulating IgG autoantibodies against type VII collagen, the major component of anchoring fibrils (see Fig. 28.3A). In addition, titers of anti-type VII collagen antibodies parallel disease activity in EBA patients, and neonates of mothers with EBA can develop transient blisters due to diaplacental transfer of anti-type VII collagen IgG autoatibodies[74,77].

Type VII collagen is located within the lamina densa and sublamina densa region of the BMZ (see Fig. 28.2). It is composed of three identical α-chains, each of which consists of a central 145 kDa collagenous triple helical segment, flanked by a large 145 kDa non-collagenous NH2-terminal domain (NC1) and a short 30 kDa COOH-terminal region (NC2). Patients' autoantibodies target immunodominant epitopes within the NC1 domain of the protein. However, reactivity with either the central collagenous domain or the NC2 domain is also observed, albeit rarely. It is, as yet, unclear if binding activity to certain antigenic regions of the molecule correlates with a distinct clinical phenotype (see below).

In vitro, EBA autoantibodies, together with the complement system and neutrophil elastase and gelatinase B, are able to mediate leukocyte infiltration (via FcγRIV expression) and dermal–epidermal separation. In mice, studies involving passive transfer of antibodies or active immunization with autologous type VII collagen have shown that autoantibodies to type VII collagen are capable of inducing dermal–epidermal separation, i.e. are pathogenic[76,77].

EBA autoantibodies may also directly interfere with the association and assembly of type VII collagen molecules into anchoring fibrils and/or by critically affecting the interactions between type VII collagen and other matrix proteins such as laminin 332, fibronectin, or type IV collagen.

As in the case of other autoimmune diseases, certain HLA class II alleles appear to be more prevalent in EBA, e.g. DRB1*15:01 and DR5 in White individuals and African-Americans or DRB1*13 in Koreans. It is likely that the expression of distinct HLA alleles has a critical impact on the susceptibility to developing EBA. The observation that deficient expression of type VII collagen in patients with various forms of dystrophic EB causes skin fragility and dermal–epidermal separation demonstrates unequivocally the importance of this protein in maintaining the integrity of the epidermal BMZ[77].

Clinical Features

EBA usually occurs in adult patients, although pediatric cases have been reported. Cutaneous manifestations are heterogeneous and may mimic other bullous diseases[77,78].

The classic presentation is that of a *non-inflammatory mechanobullous disease* characterized by the development of acral blisters that heal with atrophic scarring, milia formation, and dyspigmentation[77]. Cutaneous blisters, which may become hemorrhagic, and evolving erosions appear within non-inflamed skin or on areas of scarring. They are localized to trauma-prone surfaces, especially the elbows, knees, and dorsal aspects of the hands, occiput, back, feet, and toes (Fig. 30.18). As in inherited dystrophic EB, acral involvement in EBA may be mutilating, leading to a "mitten" deformity of the digits, webbing between adjacent fingers or toes (pseudosyndactyly), nail dystrophy, and complete

Downloaded for Anonymous User (n/a) at Egyptian Knowledge Bank from ClinicalKey.com by Elsevier on March 10, 2024. For personal use only. No other uses without permission. Copyright ©2024. Elsevier Inc. All rights reserved.

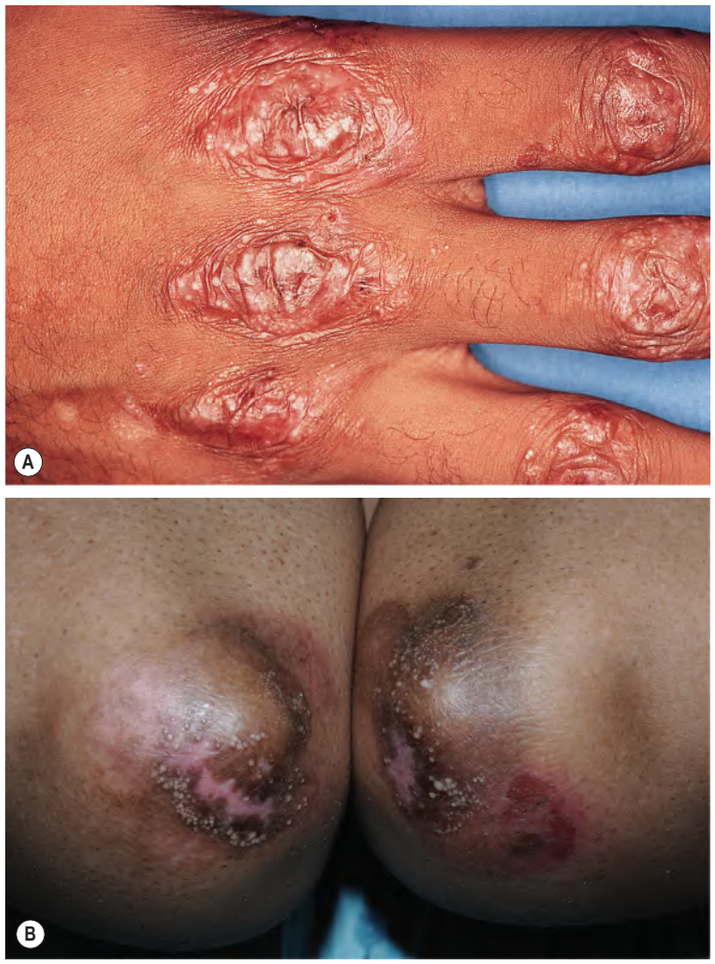

Fig. 30.18 Epidermolysis bullosa acquisita – mechanobullous presentation. **A** Milia and scarring that favor sites of trauma overlying joints, in association with skin fragility. Note the resemblance to dystrophic epidermolysis bullosa. **B** Postinflammatory hyperpigmentation, mild scarring, and milia in sites of trauma in a patient with systemic lupus erythematosus. Note the ruptured bulla on the left elbow. *B, Courtesy Kalman Watsky, MD.*

Fig. 30.19 Epidermolysis bullosa aquisita – inflammatory presentation. Widespread erythematous plaques, some of which have erosions and hemorrhagic crusts. Although there is accentuation on the elbows, the differential diagnosis would include bullous pemphigoid. *Courtesy Lorenzo Cerroni, MD.*

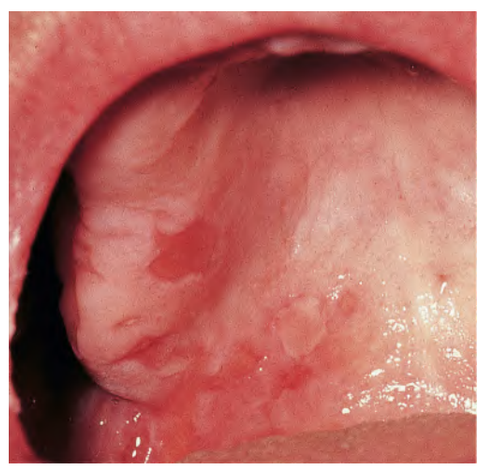

Fig. 30.20 Epidermolysis bullosa acquisita – oral involvement. Multiple erosions of the palate reminiscent of mucous membrane (cicatricial) pemphigoid. *Courtesy C. Prost, MD.*

nail loss. Scalp involvement occurs in up to 20% of patients, and, in isolated cases, extensive non-healing erosions with scarring alopecia have been described.

Several *inflammatory subtypes* of EBA have also been described, which may occur more frequently than the mechanobullous form[77,78]. The *BP-like presentation* is the most common inflammatory form of EBA[77–79]. It is characterized by widely distributed, pruritic vesicles and bullae on an erythematous base. Any cutaneous site may be involved, as well as the oral mucosa. Lesions heal without milia or atrophic scars (Fig. 30.19).

Other inflammatory subtypes of EBA are quite uncommon[77–79] and include those whose presentation resembles MMP, the Brunsting–Perry variant of MMP with scarring alopecia, and LABD with a polymorphous bullous eruption and a linear band of IgA deposits along the BMZ. Of note, during the course of the disease, the clinical features can convert from one variant to another or, alternatively, a mixture of inflammatory and non-inflammatory features may coexist.

Mucous membrane involvement occurs not only in MMP-like EBA, but is also observed in up to 50% of patients with the mechanobullous and BP-like presentations[77–79]. Erosions and intact vesicles may be seen in the mouth (Fig. 30.20), larynx and esophagus, and they may lead to dysphagia and laryngeal stenosis. Ocular involvement with severe cicatrizing conjunctivitis and blindness have been reported in the MMP-like phenotype[77,80]. Lastly, features of childhood EBA have substantial overlap with those observed in childhood BP and LABD.

In some reports, a number of systemic diseases have been described in association with EBA, particularly Crohn disease and ulcerative colitis (up to 30% of cases) and, more rarely, myeloma, systemic LE, rheumatoid arthritis, thyroiditis and diabetes mellitus[77].

Diagnosis and Differential Diagnosis

Light microscopy and electron microscopy

By light microscopy, biopsy specimens of bullae show a subepidermal cleavage. In the BP-like or MMP-like variants of EBA, there is a variable inflammatory infiltrate within the dermis, composed predominantly of neutrophils admixed with eosinophils and lymphocytes. In the mechanobullous non-inflammatory lesions, there is a minimal-to-absent cellular infiltrate.

Electron microscopy studies of fresh vesicles demonstrate that dermal–epidermal cleavage occurs within the sublamina densa zone. In addition, a reduction in the number of anchoring fibrils may be observed. However, in some cases, separation within the lamina lucida has been noted, most likely reflecting the formation of a subepidermal blister at the *locus minoris resistentiae*. The level of cleavage is, therefore, not always a reliable criterion for discriminating EBA from other subepidermal bullous disorders.

Direct immunofluorescence (DIF) microscopy

DIF microscopy studies of perilesional skin demonstrate IgG deposits distributed in a continuous, rather broad, linear pattern along the epidermal BMZ. Less commonly, linear deposits of C3, IgA, or IgM are found. In salt-split skin preparations of perilesional skin, the immune deposits are typically located on the dermal side of the cleavage. A u-serrated immune deposition pattern at the epidermal BMZ is very helpful in differentiating EBA from the other subepidermal bullous diseases, i.e. the "pemphigoids", which have an n-serrated pattern of immunoreactants

Downloaded for Anonymous User (n/a) at Egyptian Knowledge Bank from ClinicalKey.com by Elsevier on March 10, 2024. For personal use only. No other uses without permission. Copyright ©2024. Elsevier Inc. All rights reserved.

at the BMZ. Finally, the FOAM technique (see above), employing a confocal laser scanning microscope, localizes the immunoreactants to the level of the BMZ where type VII collagen is expressed[77].

Indirect immunofluorescence (IIF) microscopy

By standard IIF, circulating anti-BMZ antibodies can be detected in ~50% of patients with EBA. They are primarily of the IgG class, but serum IgA autoantibodies have also been reported. By IIF on salt-split skin, circulating IgG or IgA antibodies bind to the dermal side of the artificial blister[30,77,79,81]. Although not often available, testing of patients' sera either against a panel of skin substrate specimens lacking distinct basement membrane molecules (e.g. BP180, type VII collagen, laminin 332) or against HEK cells transfected with the recombinant NC1 domain of type VII collagen can prove helpful in characterizing the antigens targeted by circulating autoantibodies.

Immunoelectron microscopy

Immunoelectron microscopy has traditionally been considered the "gold standard" for diagnosing EBA, especially when circulating autoantibodies are absent and therefore cannot be characterized by IIF microscopy, immunoblot, or ELISA (see below)[77]. By immunogold techniques, which allow a more precise localization than peroxidase labeling, EBA autoantibodies specifically bind to the anchoring fibrils and the lamina densa where anchoring fibrils originate and terminate (see Fig. 28.3A).

Other immunochemical studies, including ELISA

In Western immunoblot analyses of dermal extracts, serum autoantibodies from patients with EBA were found to bind to proteins of ~290 kDa and, less frequently, 145 kDa. These proteins have been clearly shown to correspond to type VII collagen and its NH2-terminal NC1 subdomain, respectively[77,81]. Epitope mapping studies using recombinant forms of type VII collagen have demonstrated that immunodominant epitopes are located within the NC1 domain[81]. ELISAs are now available, utilizing either the recombinant NC1 domain of type VII collagen or a combination of recombinant NC1 and NC2 domains[82,83]; these assays exhibit high specificity (>96%) and are likely more sensitive than IIF microscopy studies utilizing salt-split skin[83]. Serum concentrations of collagen VII-specific IgG autoantibodies, as determined by ELISA, may correlate with disease severity[77].

Differential diagnosis

EBA may be confused with inherited dystrophic EB, BP, MMP, LABD, porphyria cutanea tarda, pseudoporphyria, or rare variants of porphyria (e.g. porphyria variegata). Clinically, the mechanobullous type of EBA most closely resembles mild dominant dystrophic EB, but the lack of a family history, late onset, and the positive DIF findings generally allow for distinction. However, some patients with inherited EB do develop autoantibodies against type VII collagen. The involvement of the hands may mimic porphyria cutanea tarda, but the latter can easily be excluded by porphyrin studies. Occasionally, patients with EBA on incriminating medications are misdiagnosed as having pseudoporphyria. The inflammatory type of EBA is clinically indistinguishable from BP, anti-p200 (anti-laminin γ1) pemphigoid, or MMP, including the Brunsting–Perry variant. These conditions may be distinguished by u-serrated versus n-serrated DIF pattern analysis, FOAM technique, ELISA, IIF with salt-split skin as a substrate, Western immunoblot analysis of both epidermal and dermal extracts, and direct immunoelectron microscopy studies[77,84].

Bullous systemic LE usually presents as a transient, widespread, inflammatory subepidermal blistering condition (see Ch. 41), and, less frequently, as a mechanobullous eruption with milia formation and scarring[75,77]. In a number of these cases, circulating autoantibodies show binding to type VII collagen and the possibility of systemic LE-associated EBA could be considered. In addition to differences in histology, adult EBA exhibits a poor response to treatment, while a significant improvement following initiation of dapsone or azathioprine therapy is generally seen in patients with bullous systemic LE[85].

Treatment

Treatment of EBA is difficult and often unsatisfactory. Because of the rarity of the condition, most data on treatment are based on anecdotal reports[67,74,77]. Systemic corticosteroids and immunosuppressive agents, such as azathioprine, methotrexate, mycophenolate mofetil, cyclophosphamide or, more recently, rituximab, are sometimes helpful in controlling the BP-like variant of EBA, which may eventually go into clinical remission. Colchicine, dapsone, and cyclosporine have also been reported to have some benefit. In patients with severe EBA unresponsive to conventional immunosuppressive therapy, IVIg ± rituximab may prove effective[77,85]. A combination of dapsone plus prednisolone has been recommended by some authors for the treatment of childhood EBA[74].

eFig. 30.1 Bullous pemphigoid – bullous presentation. A Classic presentation with multiple tense bullae arising on normal and erythematous skin. Several of the bullae have ruptured, leaving circular erosions. **B** Multiple tense bullae that contain serous fluid arising whithin an area of erythema in addition to hemorrhagic crusts. *B, Courtesy Kalman Watsky, MD.*

eFig. 30.2 Bullous pemphigoid. Fresh blisters are tense while older ones have become flaccid or led to erosions. They are arising with large areas of erythema.

eFig. 30.3 Bullous pemphigoid – urticarial (and bullous) presentation. Firm annular urticarial plaques. There is also subtle crusting.

eFig. 30.4 Bullous pemphigoid – eczematous presentation. Large pink eczematous plaques on the trunk and upper extremities.

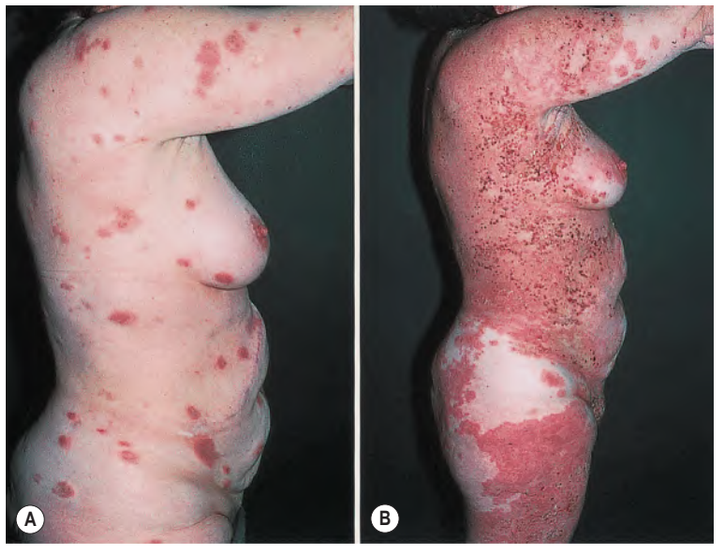

eFig. 30.5 Bullous pemphigoid – progression of disease. A Urticarial, infiltrated and annular erythematous plaques on the trunk and upper extremity. **B** Generalized eruption with blisters as well as numerous erosions and hemorrhagic crusts in the same patient later in the course of the disease.

eFig. 30.6 Bullous pemphigoid. A Excoriated eczematous lesions on the upper extremity. **B** Confluent plaques with tense blisters in the inguinal area and inner aspect of the thighs in the same patient.

eFig. 30.7 Oral mucosal involvement (desquamative gingivitis) in a patient with bullous pemphigoid. *Courtesy Mark Bernstein, MD.*

eFig. 30.8 Childhood bullous pemphigoid. A predominance of acral involvement is often seen in infants. *Courtesy Julie V. Schaffer, MD.*

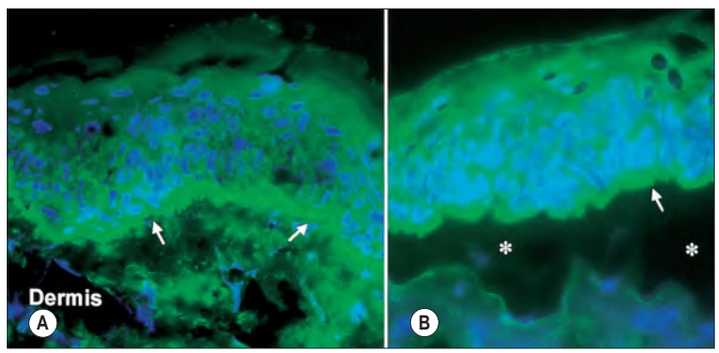

eFig. 30.9 Bullous pemphigoid – direct and indirect immunofluorescence microscopy. A Direct immunofluorescence microscopy studies of perilesional skin demonstrating linear continuous deposits of IgG along the epidermal basement membrane zone (arrows). The same pattern of labeling is observed in cicatricial pemphigoid and epidermolysis bullosa acquisita. **B** Indirect immunofluorescence microscopy study utilizing salt-split normal human skin as a substrate. IgG autoantibodies from the patient's serum are bound to the epidermal side (roof) of the split (arrow). The level of the artificial subepidermal separation is indicated by asterisks. The same pattern of labeling is observed in a subset of patients with cicatricial pemphigoid. Cell nuclei are stained blue.

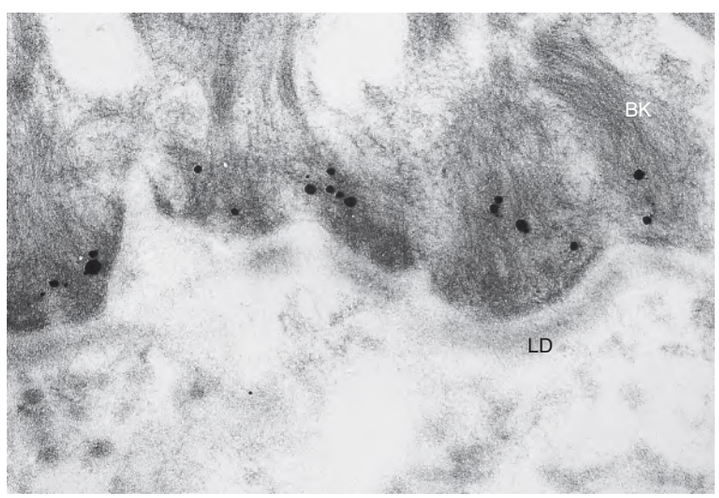

eFig. 30.10 Bullous pemphigoid – indirect immunoelectron microscopy utilizing immunogold labeling. Autoantibodies directed against BP230 specifically label the hemidesmosomal plaque of the hemidesmosomal adhesion complex (gold labeling = black dots). BK, basal keratinocyte; LD, lamina densa. *Courtesy Professor H. Shimizu.*

eFig. 30.11 Mucous membrane pemphigoid. Typical ocular involvement as manifested by fibrous tracts, representing partial or incomplete symblepharon.

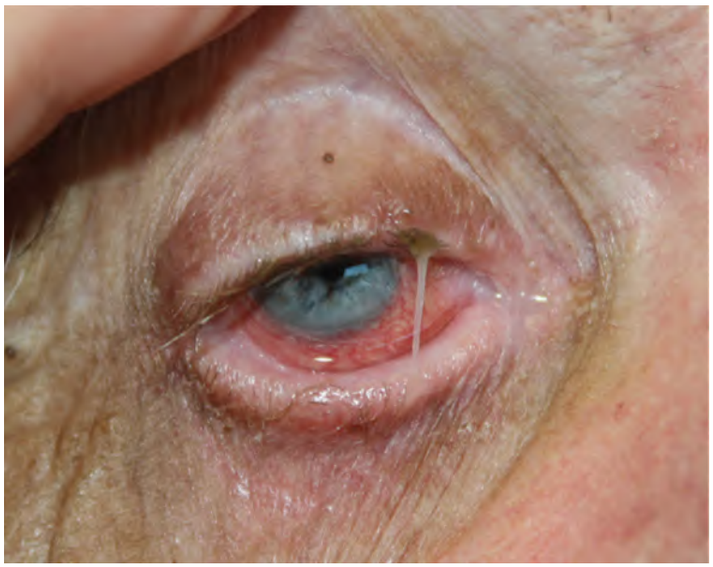

eFig. 30.12 Mucous membrane pemphigoid. Thickening of the lower eyelid with ectropion and exudative conjunctivitis. *Courtesy Jeffrey P. Callen, MD.*

eFig. 30.13 Mucous membrane pemphigoid. Desquamative gingivitis can be the presenting sign of the disease. *Courtesy Jeffrey P. Callen, MD.*

eFig. 30.14 Mucous membrane pemphigoid. Erythema and erosions of the gingival margins (desquamative or erosive gingivitis).

eFig. 30.15 Mucous membrane pemphigoid. Cutaneous involvement of the scalp with scarring and atrophy resulting in alopecia.

eFig. 30.16 Mucous membrane pemphigoid. Irregularly shaped ulceration within an area of scarring on the mid chest. Multiple sites of scarring point to chronicity. *Courtesy Michael Gowen, MD.*

eFig. 30.17 Epidermolysis bullosa acquisita in a patient with systemic lupus erythematosus. Postinflammatory hyperpigmentation, milia and scarring that favor sites of trauma overlying joints. Note the resemblance to dystrophic epidermolysis bullosa. *Courtesy Kalman Watsky, MD.*

eFig. 30.18 Epidermolysis bullosa acquisita – inflammatory bullous pemphigoid-like presentation. Bullae and circular erosions in a patient with multiple myeloma.

arch 10,
erved.